



Treatment of the Moderate Lumbar Spinal Stenosis with an Interspinous Distraction Device IMPALA[®]

Haso Sefo^{1*}, Mersad Barucija¹, Edin Hajdarpasic¹, Mirsad Muftic²

¹Department of neurosurgery, Clinical Center University of Sarajevo, Bolnicka 25, Sarajevo, Bosnia and Herzegovina.

²Faculty of Health Studies, University of Sarajevo, Bolnicka 25, Sarajevo, Bosnia and Herzegovina

ABSTRACT

Introduction: The aim of this study was the evaluation of symptom improvements in patients with moderate lumbar spinal stenosis, who consecutively underwent placement of interspinous distraction device IMPALA[®].

Methods: This study included a total of 11 adult patients with moderate lumbar spinal stenosis. Clinical evaluations were performed preoperatively and 3-months after surgery using the Visual Analogue Scale (VAS) and Oswestry Disability Index (ODI).

Results: The mean preoperative VAS was 7.09 and fell to 2.27 a 3-months after surgery. The mean preoperative ODI was 59.45 fell to 20.72 a 3-months after surgery.

Conclusions: Using the IMPALA[®] device in patients with moderate lumbar spinal stenosis is a minimal invasive, effective and safe procedure. Clinical symptoms were improved 3 months after surgery.

Keywords: Spinal stenosis, Minimal invasive procedure, Interspinous device, Impala[®]

INTRODUCTION

Lumbar spinal stenosis (LSS) is a condition involving the narrowing of either the spinal canal or neural foramina. The stenosis is caused by hypertrophy of the ligament flavum and facet joints, osteophytes, spondylolisthesis and disc protrusion, which results in nerve compression in one or more motion segments (1). The most common symptom associated with LSS is neurogenic intermittent claudication

(NIC) and typically concerns patients at the age of 50 or above. NIC is defined as pain or numbness in the buttocks, thighs and/or legs brought on by either prolonged standing or exercise in the erect posture. The symptom is typically relieved by various manoeuvres that flex the lumbar spine, such as bending forward or sitting, which increases the spinal canal significantly. The best treatment of NIC due to lumbar stenosis remains controversial. Nonoperative therapy like epidural steroid injections, nonsteroidal anti-inflammatory medication, analgesics, physical therapy, and spinal manipulation, is frequently performed. Decompressive surgery with or without fusion is the current 'gold standard' treatment for moderate to severe symptomatic LSS (1-4). The first interspinous device, the Wallis system (Abbott

*Corresponding author: Haso Sefo, Department of neurosurgery, Clinical Center University of Sarajevo, Bolnicka 25, Sarajevo, Bosnia and Herzegovina. Phone:+38733297343; E-mail: haso_sefo@hotmail.com

Submitted 9 April 2013 / Accepted 1 August 2013



Spine), was developed in 1986 and used in patients with recurrent disc herniation. Recently, a new class of spinal devices called interspinous spacers (ISPs) has been introduced. The painful repercussions of lumbar stenoses can often be mitigated by a combination of decompression and widening of the intervertebral foramen. This permanent widening is achieved by an interspinous spacer (5,6). IMPALA® made by Signus fulfils this function. It is a three-part implant which is inserted between two spinous processes. The natural structures are left largely intact in this procedure: the supraspinous ligament is retained and the bony structures are not damaged. Thus mobility is maintained in flexion and rotation. Pain occurring in extension is alleviated.

The positive aspects of using IMPALA® are: tensioning the interspinous ligaments, separating the posterior elements with accompanying unloading of the facet joints, reducing facet pain, widening the intervertebral foramen and thus decompressing the vertebral canal and relieving the load on the disc, reducing disc pain and reducing the risk of prolapse. IMPALA® is made of PEEK-OPTIMA®, a biocompatible plastic which combines several advantages. The elasticity module is similar to that of cortical bone. In addition, plastic ensures artefact-free MRT imaging. Appropriate markers are incorporated to enable the position of the implant to be determined by X-ray.

The indication for IMPALA® includes radiologically confirmed, moderate stenoses of the vertebral canal in the L1-S1 region, of varying genesis, with neurological impairment, resulting in claudication and/or radicular symptoms. The procedure is limited to a maximum of two levels (7).

METHODS

Patients

The study included a total of 11 adult patients with moderate lumbar spinal stenosis, who consecutively underwent placement of interspinous distraction device at 1 or 2 levels between October 2011 and February 2013 at Department of neurosurgery, Clinical Center University of Sarajevo.

Lumbar spinal stenosis in all patients was confirmed by MRI scans. All patients had lateral and AP standing roentgenograms of the lumbar spine before sur-

gery as well as after surgery (Figure 1).

Clinical evaluations were performed preoperatively and 3-months after surgery using the Visual Analogue Scale (VAS) and Oswestry Disability Index (ODI) (8).

In our institution, patients are admitted for 24 hours before the day of the procedure. The patient is out of bed few hours after surgery and discharged on second postoperative day. Usually, the patients had regular follow up at 1 and 3 months.

Operative techniques

The operation is typically performed under general anaesthetic. It is advantageous if the patient is completely relaxed. The patient is placed in the genupectoral position on a radiolucent table. After identification of the segment affected and radiological assessment, an incision is made in the midline. The segment to be operated on is exposed on one side, leaving the supraspinous ligament intact. With the aid of the curettes, the interspinous ligament can then be opened and the muscles detached on the opposite side. This makes a unilateral approach possible. The distractor is then inserted as far as possible between the spinous processes. Complete muscular relaxation is necessary to attain optimal distraction at the coronal level. The distraction should relieve the load on the posterior elements of the vertebral column and result in foraminal decompression. The appropriate size of implant is determined using the distractor in the locked position and the trial instrument. The aim is to use the largest size of implant possible. Thereafter, interspinous distractor was inserted tightly into the interspinous space. The implant is finally secured by attaching the locking plate. A final X-ray check is made on two planes.

RESULTS

A total of 11 patients (7 female and 4 male) with spinal stenosis were included in the study. The mean age was 52 (range 42-63). In 7 patients (L4-L5 level), in 2 patients, (L3-L4 and L4-L5 levels) and in 2 patients (L4-L5 and L5-S1 levels) were implanted (Table 1). The mean preoperative VAS was 7.09 and fell to 2.27 a 3-months after surgery (Figure 2). The mean preoperative ODI was 59.45 fell to 20.72 3-months after surgery (Figure 3). There was a significant improvement in the VAS and ODI scores.

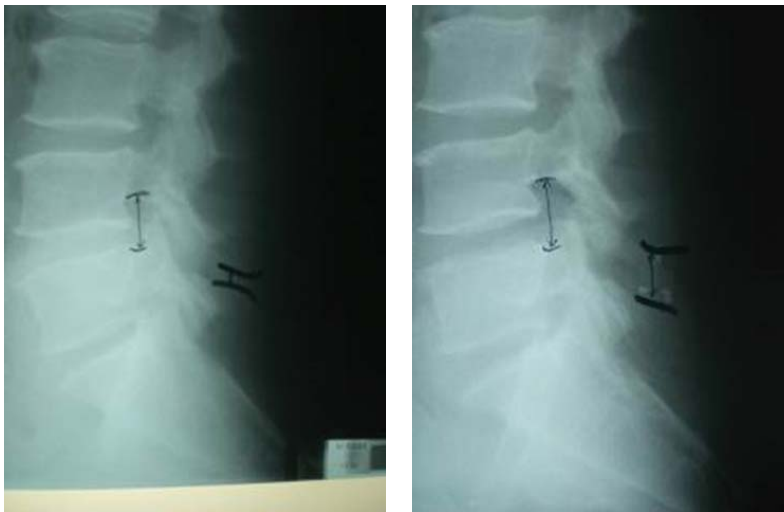

FIGURE 1. Preoperative (left) and postoperative (right) lateral roentgenograms. (Lateral roentgenograms after implantation of interspinous device shows separation of the posterior elements with accompanying unloading of the facet joints, widening the intervertebral foramen and thus decompressing the vertebral canal and relieving the load on the disc).

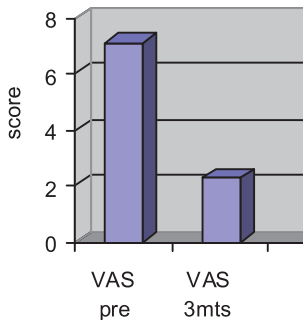


FIGURE 2. The symptom improvement measured by VAS scale. VAS pre: preoperative VAS score; VAS 3mts: VAS score 3 months after surgery.

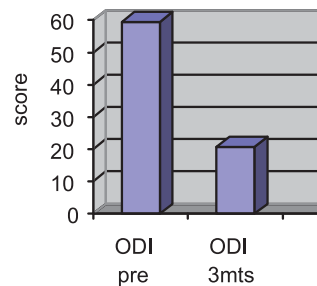


FIGURE 3. The symptom improvement measured by ODI scale. ODI pre: preoperative ODI score; ODI 3mts: ODI score 3 months after surgery.

TABLE 1. Clinical Outcomes of the Patients

Age	Sex	Level(s)	VAS pre	VAS 3mts	ODI pre	ODI 3mts
51	F	L4-L5	6	1	44	10
56	M	L4-L5	7	2	52	16
58	M	L4-L5	8	3	56	22
51	M	L4-L5	6	2	48	14
63	F	L3-L4 L4-L5	8	4	80	32
54	F	L4-L5	6	2	50	16
54	F	L4-L5	7	2	56	22
45	M	L4-L5 L5-S1	8	3	78	30
50	F	L4-L5	8	2	70	24
48	F	L4-L5 L5-S1	7	2	62	22
42	F	L3-L4 L4-L5	7	2	58	20

DISCUSSION

The interspinous implantation is less invasive than laminectomy as a gold standard in classical surgical treatment of spinal stenosis. In general, materials are well tolerated. There were no broken or permanently deformed implants in any of the cases. There was just one case of migration of interspinous-device because of placement of smaller size of device and that patient was underwent to surgery again. Compared with literature-reported outcomes of laminectomy surgery there are significant differences in operative time, estimated blood loss, hospital stay, complication rate and reoperation rates favouring the interspinous-device (10-15).

In our study there was significant improvement of symptoms according VAS and ODI scores after interspinous-device placement. It was also conformed in a prospective and randomized multi-center study made by Zuckerman et al.(16) showed also a success rate of 59% at 1 year postsurgery with an interspinous implant. This result was much better than that of 12% in the control patients who were treated only conservatively.

CONCLUSIONS

Using the IMPALA® device in patients with moderate lumbar spinal stenosis is a minimal invasive and safe procedure. Clinical symptoms were improved 3 months after surgery. The decompression of the lumbar spine with IMPALA® bridges the cleft between usual conservative therapy and aggressive surgical treatment methods reducing symptoms with minimal surgical risks.

COMPETING INTERESTS

The authors declare no conflict of interest.

REFERENCES

- Porter RW. Spinal stenosis and neurogenic claudication. *Spine*.1996;21:2046–2052.
- Schonstrom N, Lindahl S, Willen J, Hansson T. Dynamic changes in the dimensions of the lumbar spinal canal: an experimental study in vitro. *J Orthop Res*. 1989;7:115–121.
- Verbiest H. A radicular syndrome from developmental narrowing of the lumbar vertebral canal. *J Bone Joint Surg*. 1954;36-B:230–237.
- Inufusa A, An HS, Lim TH, Hasegawa T, Haughton VM, Nowicki BH. Anatomic changes of the spinal canal and intervertebral foramen associated with flexion-extension movement. *Spine*.1996;21:2412–2420.
- Boeree N. Dynamic stabilization of the lumbar motion segment with the Wallis system. Scientific presentation at the Annual Meeting of the Spine Arthroplasty Society; 2005 May 4-7; New York, NY.
- Eif M, Schenke H. The Interspinous-U: Indications, experience, and results. Scientific presentation at the Annual Meeting of the Spine Arthroplasty Society; 2005 May 4-7; New York, NY.
- Signus Deutschland GmbH. Products: Posterior instrumentation. (homepage on the Internet). No date. Available from http://www.signus-med.de/fileadmin/pdf/products/IMPALA_DB_EN_L04_2012_07-02.pdf
- Fairbank JC, Pynsent PB, The Oswestry Disability Index. *Spine*. 2000; 25(22):2940-2952.
- Amundsen T, Weber H, Lilleas F, Nordal HJ, Abdelnoor M, Magnaes B. Lumbar spinal stenosis. Clinical and radiologic features. *Spine*.1995; 20(10): 1178-1186.
- Benz RJ, Ibrahim ZG, Afshar P, Garfin SR. Predicting complications in elderly patients undergoing lumbar decompression. *Clin Orthop*. 2001;384:116–121
- Deyo RA, Cherkin DC, Loeser JD, Bigos SJ, Ciol MA. Morbidity and mortality in association with operations on the lumbar spine. The influence of age, diagnosis, and procedure. *J Bone Joint Surg Am*. 1992;74(4):536–543.
- Postacchini F, Cinotti G, Perugia D, Gumina S. The surgical treatment of central lumbar stenosis: multiple laminotomy compared with total laminectomy. *J Bone Joint Surg*. 1993;74:386–392.
- Jonsson B, Annertz M, Sjoberg C, Strömqvist B. A prospective and consecutive study of surgically treated LSS. Part II: Five-year follow-up by an independent observer. *Spine*.1997;22: 2938–2944.
- Katz JN, Lipson SJ, Larson MG, McInnes JM, Fossel AH, Liang MH. The outcome of decompressive laminectomy for degenerative lumbar stenosis. *J Bone Joint Surg Am*. 1991;73:809–816.
- Hu RW, Jaglal S, Axcell T, Anderson G. A population-based study of reoperations after back surgery. *Spine*. 1997;22(19):2265–2271
- Zucherman JF, Hsu KY, Hartjen CA, Mehalic TF, Implicito DA, Martin MJ, Johnson DR 2nd, Skidmore GA, Vessa PP, Dwyer JW, Puccio S, Cauthen JC, Ozuna RM. A prospective randomized multicenter study for the treatment of lumbar spinal stenosis with the X STOP interspinous implant: 1-year results. *Eur Spine J*. 2004; 13:22-31.