



Lymphangiogenesis in breast carcinoma is present but insufficient for metastatic spread

Mirsad Dorić*, Suada Kuskunović-Vlahovljak, Svjetlana Radović, Ajna Hukić, Mirsad Babić, Edina Lazović-Salčin

Institute of Pathology, Faculty of Medicine, University of Sarajevo, Čekaluša 90, 71000 Sarajevo, Bosnia and Herzegovina

ABSTRACT

Introduction: The lymphatic vasculature is an important route for the metastatic spread of human cancer. However, the extent to which this depends on lymphangiogenesis or on invasion of existing lymph vessels remains controversial. The goal of this study was to investigate the existence of lymphangiogenesis in invasive breast carcinoma: by measuring the lymphatic vessels density (LVD) and lymphatic endothelial cell proliferation (LECP) and their correlation with various prognostic parameters in breast cancer, including lymphovascular invasion (LVI).

Methods: Lymphatic vessels density was investigated in 75 specimens of invasive breast carcinoma by immunostaining for D2-40 using the Chalkley counting method. Endothelial proliferation in lymphatic vessels was analyzed by dual-color immunohistochemistry with D2-40 and Ki-67.

Results: Decrease of intra and peritumoral LVD in invasive breast carcinoma compared to fibrocystic breast disease was detected ($p=0.002$). Lymphatic endothelial cell proliferation was significantly higher in invasive breast cancer ($p=0.008$) than in the fibrocystic breast disease. LECP showed a correlation with histological grade of the tumor ($p=0.05$). Involvement of axillary lymph nodes with metastatic tissue was in strong correlation only with existence of lymphatic vascular invasion ($p=0.0001$).

Conclusion: These results suggest that development of breast cancer promotes proliferation of lymphatic endothelial cells whose level correlates with histological grade of tumor, but in a scope that is insufficient to follow growth of tumor tissue that invades them and destruct them. This might explain the decrease of lymphatic vessels density.

Keywords: breast carcinoma; D2-40; Ki-67; lymphangiogenesis

INTRODUCTION

The major cause of death from breast cancer is dissemination of the primary tumor leading to forma-

tion of metastases. Spread to axillary lymph nodes is often the first step of generalization (1). Tumor-associated lymphatic vessels are considered to be the main route of tumor cells to axillary lymph nodes (2). Recently, lymphangiogenesis, the formation of new lymphatic vessels, has become a new research frontier in tumor metastasis since the discovery of the two major lymphatic vessel growth factors-C (VEGF-C) and -D (VEGF-D), as well as reliable

*Corresponding author: Mirsad Dorić
Institute of Pathology, Faculty of Medicine, University of Sarajevo,
Čekaluša 90, 71000 Sarajevo, Bosnia and Herzegovina
Phone: 061/220-428
E-mail: mdoric@lsinter.net

Submitted March 27 2014/Accepted April 18 2014



lymphatic markers that have allowed observation and isolation of lymphatic endothelium (3).

Specific lymphatic endothelial markers have become available, making analysis of lymphatics in cancer possible. D2-40 antibody was reported to detect a fixation-resistant epitope on a 40 kDa O-linked sialoglycoprotein expressed in lymphatic endothelium but not blood vessels, and can be used to assess lymphangiogenesis specifically in conventionally processed formalin-fixed and paraffin-embedded tissue specimens (4,5).

Although proliferating lymphatics, that promote nodal metastasis, have been demonstrated in experimental breast tumors, it has yet to be determined whether the same phenomena occurs in spontaneous human breast cancers. The existence of lymphangiogenesis in breast carcinoma is one of the most controversial areas in the breast cancer literature.

The aim of this study was to investigate existence of lymphangiogenesis in invasive breast carcinoma: by measuring lymphatic vessels density (LVD) and lymphatic endothelial cell proliferation (LECP), and their correlation with various prognostic parameters in breast cancer, including lymphovascular invasion (LVI).

METHODS

Clinico-pathological data

Seventy-five cases of invasive carcinoma (IC) of the breast were identified by searching the database of the Institute of Pathology, Medical faculty of Sarajevo, Bosnia and Herzegovina. All patients with IC of the breast underwent partial or total mastectomy with axillary lymph node dissection. No neoadjuvant chemotherapy or radiotherapy was administered before the surgical treatment. Ten samples fibrocystic breast tissue were used as a control group.

The patient age at the time of surgery ranged from 37 to 87 years, (mean 59.43 years). Clinicopathological characteristics of the studied cases are shown in Table 1.

Immunohistochemical staining

Double-labeling immunohistochemical staining. Four-micron-thick paraffin sections were taken on charged

TABLE 1. Clinicopathological characteristics of the studied cases

Variable	Cases	(%)
Tumor size (AJCC)		
pT1	41	54.7
pT2	32	42.7
pT3	2	2.7
Tumor type		
Ductal (NOS)	57	76
Lobular	8	10.7
Medullary	4	5.3
Neuroendocrine	3	4
Mucinous	2	2.7
Tubular	1	1.3
Grade		
1	23	30.7
2	33	44
3	19	25.3
ER status		
Positive	48	64.2
Negative	27	35.8
PR status		
Positive	45	54.7
Negative	30	45.3
HER2 status		
0	43	50.6
1 +	13	15.3
2 +	3	3.5
3 +	16	18.8
Ki-67		
Negative	3	4
Positive	72	96
bcl2		
Negative	41	54.7
Positive	34	45.3
p53		
Negative	41	54.7
Positive	34	45.3
Nodal status		
Negative	68	90.7
Positive	7	9.3
Lymphovascular invasion (LVI)		
Negative	46	61.3
Positive	29	38.7

slides, deparaffinized in xylene, and hydrated with graded alcohols and distilled water. To detect divid-

ing lymph vessel endothelial cells, a double immunostaining for D2-40 and the proliferation marker Ki-67 was done. First, a monoclonal antibody directed at Ki-67 (Dako Cytomation; dilution 1:60, klon MIB 1) was applied to the rehydrated paraffin sections for 15 minutes after antigen retrieval in TBS (tris)-EDTA buffer (pH 9.0) at 95°C. Sections were incubated with EnVision+ Dual Link solution before development with diaminobenzidine (Dako Cytomation). Sections were then stained with the D2-40 antibody (Dako Cytomation; dilution 1:100) for 60 minutes. EnVision System alkaline phosphatase and Fast Red chromogen (Dako Cytomation) were used to visualize binding of this second antibody.

Immunostaining for ER, PR, HER2, p53, bcl-2 and Ki-67. The primary antibody against the estrogen receptor was performed in humidity chamber in EDTA buffer (pH 9) for 40 min. (clone 1D5, Dako Cytomation; dilution 1:30). The protocols for staining PR, Ki-67, and p53 included a microwave antigen retrieval step, 3 times for 5 minutes: anti-PR (clone PgR, Dako Cytomation; dilution 1:30), anti-Ki-67 (clone MIB-1, Dako Cytomation; dilution 1:10), anti-p53 (clone DO-7, Dako Cytomation; dilution 1:5). Citrate buffer (pH 6) was used for anti-bcl-2 oncoprotein (clone 124, Dako Cytomation; dilution 1:40). The working system used was LSAB2 (labelled streptavidin biotin) – HRP and diaminobenzidine (DAB) was the chromogen used for reaction visualization.

Antigen retrieval for HER2 using HercepTest was performed following the manufacturer's protocol (Dako Cytomation).

Immunohistochemistry evaluation. The percentage of tumor cells with unequivocal nuclear staining for estrogen receptor (ER), progesterone receptor (PR), p53, Ki-67 (MIB-1), was recorded semiquantitatively (0, no staining; 1, <10%; 2, 11-33%; 3, 34-66%; 4, 67-100%). For Bcl-2 the intensity of cytoplasmic staining (0-4) and the percentage of positive cells were recorded. A cutoff value was applied to each marker to indicate positive or negative staining. A threshold of $\geq 1\%$ for ER, PR, and 10% for p53 and Ki-67 (MIB-1) was used and score of 3+ for HER2. For Bcl-2, there was little difference between the different measures of positivity (i.e., percentage

of positive cells versus intensity of staining) and a cutoff value of 10% was used.

Membranous staining was scored for HER2 according to the HercepTest (Dako) as follows: 0, no staining or faint incomplete staining in <10% cells; 1, faint incomplete staining in >10% cells; 2, weak to moderate complete staining in >10% cells; 3, strong complete staining in >10% cells. Cases scored as 2+ were considered equivocal, and retested using chromogen in situ hybridization (CISH).

Lymphatic vessels quantification

Sections stained with D2-40 were used for the evaluation of LVD using the Chalkley counting method. Each section was first scanned at low-power magnification ($\times 40$) to select the most vascularized areas; three hot spots were selected. Two authors first examined 10% of specimens to agree on which fields to be used as hot spots. A 25-point Chalkley eyepiece graticule was applied to each hot spot and oriented to permit the maximum number of points to hit on, or within the areas of immunohistochemically highlighted microvessel using $\times 200$ magnification. A Chalkley count for an individual tumor was taken as the mean value of the three graticule counts (6).

Assessment of lymphatic endothelial cell proliferation

The fractions of proliferating lymphatic endothelial cells (LECP%) were calculated in each hotspot as the number of lymphatic endothelial cells with Ki-67 stained nuclei per 100 lymphatic endothelial cells. Cases in which the average number of lymphatic endothelial cells in three hotspots was <10 were excluded for statistical analysis.

STATISTICAL ANALYSIS

Statistical analysis was performed using SPSS for Windows (version 13; SPSS, Chicago, IL, USA). Two-tailed unpaired *t* test was performed to identify the differences between two groups. One-way ANOVA test was performed for comparing the groups that were used for the *t* test. The correlations between the variables were assessed by the Spearman rank sum test. *P* values <0.05 were considered as statistically significant.

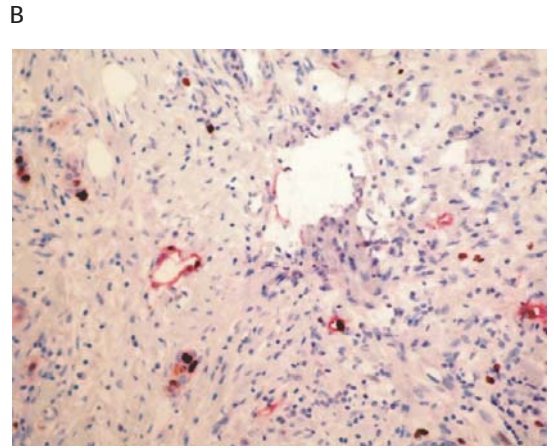
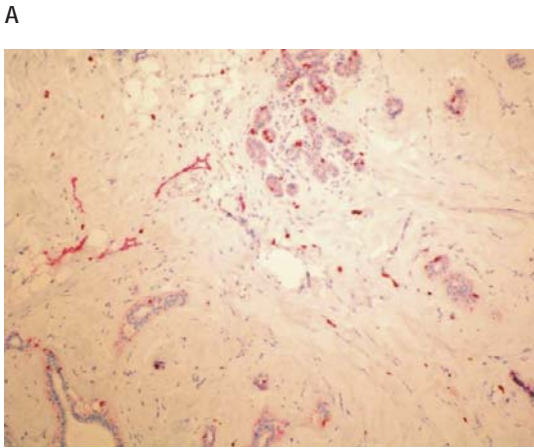


FIGURE 1. (A) The lymphatic vessels were elongated and linear, dispersed around the lobules in the interlobular stroma (D2-40 x 100). (B) D2-40/Ki-67 positive peritumoral lymphatic vessels (x 100)

RESULTS

Benign breast samples

In these 10 cases, the lymphatic vessels were dispersed around the lobules in the interlobular stroma, adipose tissue, and adjacent to blood vessels. These vessels were elongated and linear in most areas and tortuous focally. Lymphatic vessels were not identified within the intralobular stroma (Figure 1A). Lymphatic endothelial cell proliferation was observed in 3 of 10 cases.

Invasive carcinoma

Lymphatic vessels were identified within invasive tumors except in areas adjacent to preexisting ducts and lobules; the latter were interpreted as preexist-

ing vessels ‘entrapped’ within the tumor (Figure 1B). Blood vessels within the tumor mass were not associated with perivascular lymphatic vessels. The density of intratumoral and peritumoral lymphatic vessels in invasive carcinoma was significantly lower ($p=0.002$) in comparison to fibrocystic disease (Figure 2). Conversely, density of peritumoral lymphatic vessels was significantly higher in comparison to intratumoral lymphatic vessel density ($p=0.0001$).

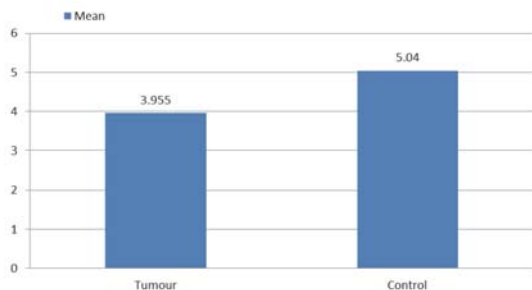


FIGURE 2. Decrease of intra and peritumoral LVD in invasive breast carcinoma compared to fibrocystic breast disease ($p=0.002$).

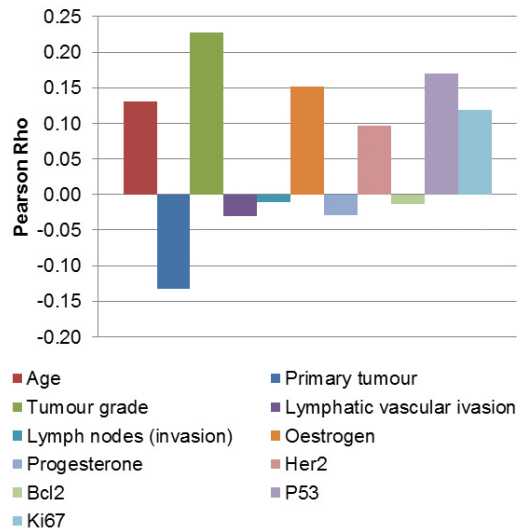


FIGURE 3. LECP show correlation with histological grade of the tumor ($p=0.05$).

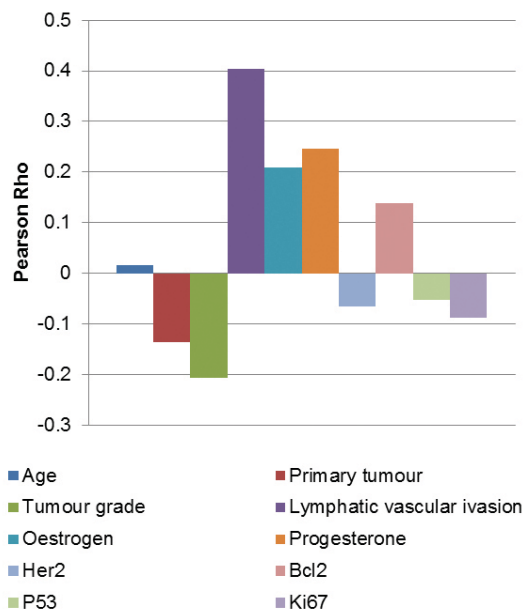


FIGURE 4. Axillary lymph node metastasis showed strong correlation only with existence of lymphatic vascular invasion ($p=0.0001$).

Lymphatic endothelial cell proliferation was observed in the fibrocystic breast disease (in 3 of 10 cases) but was significantly higher ($p=0.008$) in invasive breast cancer. LECP% showed correlation ($p=0.05$) with histological grade of the tumor (Figure 3). Significant correlation was not found between lymphatic vascular density and lymphatic endothelial cell proliferation. Involvement of axillary lymph nodes with metastatic tissue showed strong correlation ($p=0.0001$) only with existence of lymphatic vascular invasion (Figure 4).

DISCUSSION

The invasion and metastasis of tumor cells are important biological features of neoplasm and the main cause for poor prognosis and death (7). Axillary lymph node status at time of diagnosis is the most significant and durable prognostic factor in breast cancer patients (1). However, the extent to which this depends on lymphangiogenesis or on invasion of existing lymph vessels remains controversial.

Lymphangiogenesis may be assessed either by LVD or lymphatic endothelial proliferation. In the cur-

rent study, lymphangiogenesis was assessed by both these methods. We did not find an increased LVD in breast cancer. Dual immunohistochemistry using D2-40 and Ki-67 showed expression of Ki-67 in lymphatic endothelial cells indicating proliferation. The results of the present study confirmed Ki-67-positive nuclei in a proportion of lymph vessel endothelial cells, suggesting that there is indeed lymphangiogenesis in breast cancer, the most compelling evidence being the presence of proliferating lymphatic endothelial cells.

Vleugel et al. (8) and Williams et al. (9) failed to detect lymphangiogenesis in breast cancer using LYVE-1 as a marker for lymphatic vessels. Williams et al. (9) did not find 'dividing' lymphatic vessels within the tumor in their analysis of 75 cases of invasive ductal and lobular breast cancer using dual immunohistochemistry for LYVE-1 and Ki-67. In contrast, Choi et al. (10) studied LVD without differentiating between intratumoral and peritumoral lymphatic vessels in breast cancer using D2-40 antibody. They found that increased LVD correlated with several prognostic factors, including lymph node metastasis. Bono et al. (11) found intratumoral LYVE-1-positive vessels in only 12% of cases, in contrast of finding such vessels in a peritumoral location in 94% of cases. Increased number of peritumoral lymphatic vessels were associated with a poor outcome. These results are similar to those of Nakamura et al. (12) who found increased flt-4-positive vessel density to be associated with VEGF-D expression, positive nodal status, and poor prognosis.

Detection of dividing lymphatic endothelial cells became central to the current controversy on whether lymphangiogenesis occurs in breast cancer and whether lymphatic metastasis occurs through pre-existing or newly-formed lymphatic vessels (13-15). This controversy exists because neither the mere presence of pro-lymphangiogenic factors nor frequent incidence of lymph node metastasis constitutes a proof of tumor-induced, actively ongoing formation of new lymphatic vessels. Resolving this question has been sought by double staining using antibodies to specific lymphatic markers (LYVE-1 or D2-40) combined with antibodies to proliferative markers such Ki-67 (MIB-1) or PCNA. As a result, interpretation of overlapped lymphatic marker/Ki-67 positivity might depend on whether the posi-

tive cells are seen to be proliferating LEC, or dividing tumor cells that had invaded lymphatic vessels. Additional challenges in detection of proliferating LEC are: (a) a relatively low rate of vessel formation in well-established tumors; (b) a lower density and heterogeneity of tumor lymphatics compared with tumor blood vessels; and (c) variability in sprouting of new vessels at different points along the parental lymphatic vessel (16), with the latter being undetectable in two-dimensional evaluation. Moreover, the formation of new lymphatic vessels might not require endothelial mitotic division if they originate from circulating progenitors or non-endothelial cells via trans-differentiation (17).

Given these technical and biological limitations, it is not surprising that several studies failed to detect Ki-67 or PCNA markers on LYVE-1 or D2-40-labeled structures (13-15). However, evidence from several research groups also supports tumor-induced lymphangiogenesis and shows its clinical relevance to lymphatic metastasis. For instance, double Ki-67/podoplanin staining of a large panel ($N=177$) of invasive breast carcinomas determined that 29% of specimens displayed Ki-67 positive nuclei in 2.2% of intratumoral, peritumoral and peripheral lymphatics (18). Frequency of positive nuclei was strongly associated with a high lymphatic density ($p = 0.001$), LN metastasis and survival (18). An independent study detected a similar fraction of proliferating LEC (LECP%) in peritumoral lymphatics also identified LECP% as an independent prognostic factor for LN metastasis (19). Studies that compared LECP% in inflammatory and non-inflammatory breast cancers found that the former have both a higher incidence of Ki-67 positive lymphatics (80% vs. 50%) and an increased median LECP% (20, 21). Active lymphangiogenesis was also detected in positive sentinel LN (22, 23) that displayed a significantly higher median LECP% ($p < 0.001$) than uninvolved LN (23). Moreover, high frequency of Ki-67-labeled lymphatics in positive sLN was strongly associated ($p = 0.01$) with axillary metastasis (22), supporting the contention that tumor-induced lymphangiogenesis promotes dissemination from both the primary tumor and secondary metastatic sites. Nevertheless, with the exception of very active lymphangiogenesis in inflammatory breast cancer (20,21), a relatively low fraction of di-

viding lymphatic endothelial cells (2–6%) and some discrepancy between high %LVI and low %LECP in other breast cancer types suggest that both new and existing lymphatic vessels partake in lymphatic metastasis (24).

In contrast to challenges mentioned earlier in the detection of dividing LEC, enumerating lymphatic vessels seemed initially a straightforward measure of lymphangiogenesis. To assess tumor vascularity, there are several methods including counting the number of immunohistochemically stained microvessels in vascular hot spots, grading of vascular, using image analysis systems (25) and applying the Chalkley grid. The Chalkley count technique was recommended in an international consensus report because it is considered to be a simple and acceptable procedure for daily clinical use and produced lower inter-observer variability compared to the more frequently used conventional microvessel density method (26). LVD has been studied in a number of human cancers, including melanoma (27) and prostate (28). As a result, findings and interpretations from the studies that focused on infrequently occurring intratumoral lymphatic vessels (14), or those that compared a heterogeneous LVD pattern to more orderly tumor blood vessel distribution (13), fueled the debate whether lymphangiogenesis exists in breast cancer (13-15). Additional complexity arises from the fact that, in contrast to blood vessels, lymphatic vessels support spread of metastatic cells, but not tumor cell proliferation and expansion of the tumor mass. Kannigurn et al. (29) showed that microvessel density (MVD) Chalkley but not the LVD Chalkley count can be a predictive factor for axillary lymph node metastasis in breast carcinoma. Therefore, subtle increases in LVD might be missed in tumor sections set aside for immunohistochemical analysis, although they might suffice for tumor dissemination in a patient. All methods used in study of Niemiec et al. (30) for assessment of lymphangiogenesis (LVD, DLV, LVD/MVD) were correlated to each other and to parameters indicating aggressive tumor behavior (high grade, TNP, HER2 subtype, basal marker expression), hence they might be used equivalently.

The main evidence supporting the claim that lymphangiogenesis does not exist in tumors is detection of decreased LVD or absence of intratumoral lym-

phatic vessels (LV) compared with normal breast tissue (13-15). The same studies, however, reported a significant increase ($p=0.0001$) in peritumoral LVD (13,15) with some lymphatic vessels containing tumor emboli (13). There is a wide range of opinions with regard to a prognostic value of intratumoral LVD. However, a consensus seems to exist with regard to increased density of peritumoral lymphatic vessels that might be sufficient for tumor cell transit to lymph node even in the absence of intratumoral lymphatics.

CONCLUSION

The findings from this study show that lymphangiogenesis in breast cancers, measured by lymphatic endothelial cell proliferation is present, but measured by lymphatic vascular density is absent. These results suggest that development of cancer tissue in breast promotes proliferation of lymphatic endothelial cells whose level correlates with histological grade of tumor, but in a scope that is insufficient to follow growth of tumor tissue that invades them and destruct them. This might explain decrease of lymphatic vessels density.

COMPETING INTERESTS

The authors declare no conflict of interest for this study.

REFERENCES

- Donegan WL. Tumor-related prognostic factors for breast cancer. *CA Cancer J Clin.* 1997; 47:28-51.
- Nathanson SD, Zarbo RJ, Wachna DL, et al. Microvessels that predict axillary lymph node metastases in patients with breast cancer. *Arch Surg.* 2000;135:586-593.
- Stacker SA, Hughes RA, Achen MG. Molecular targeting of lymphatics for therapy. *Curr Pharm Des.* 2004;10:65-74.
- Choi WW, Lewis MM, Lawson D, Yin-Goen Q, Birdsong GG, Cotsonis GA, Cohen C, Young AN. Angiogenic and lymphangiogenic microvessel density in breast carcinoma: correlation with clinicopathologic parameters and VEGF-family gene expression. *Mod Pathol.* 2005;18:143-152.
- Kahn HJ, Marks A. A new monoclonal antibody, D2-40, for detection of lymphatic invasion in primary tumors. *Lab Invest.* 2002;82:1255-1257.
- Fox SB, Harris AL. Histological quantitation of tumour angiogenesis. *Apmis* 2004; 112: 413-430.
- Thames HD, Buchholz TA, Smith CD. Frequency of first metastatic events in breast cancer: implications for sequencing of systemic and local-regional treatment. *J Clin Oncol.* 1999;17:2649-2658.
- Vleugel MM, Bos R, van der Groep P, et al. Lack of lymphangiogenesis during breast carcinogenesis. *J Clin Pathol.* 2004;57:746-751.
- Williams CS, Leek RD, Robson AM, et al. Absence of lymphangiogenesis and intratumoural lymph vessels in human metastatic breast cancer. *J Pathol.* 2003;200:195-206.
- Choi WW, Lewis MM, Lawson D, et al. Angiogenic and lymphangiogenic microvessel density in breast carcinoma: correlation with clinicopathologic parameters and VEGF-family gene expression. *Mod Pathol.* 2005; 18:143-152.
- Bono P, Wasenius VM, Heikkilä P, et al. High LYVE-1-positive lymphatic vessel numbers are associated with poor outcome in breast cancer. *Clin Cancer Res.* 2004;10:7144-7149.
- Nakamura Y, Yasuoka H, Tsujimoto M, et al. Flt-4-positive vessel density correlates with vascular endothelial growth factor-d expression, nodal status, and prognosis in breast cancer. *Clin Cancer Res.* 2003;9:5313-5317.
- Agarwal B, Saxena R, Morimiya A, Mehrotra A, Badve S. Lymphangiogenesis does not occur in breast cancer. *Am J Surg Pathol.* 2005; 29:1449-1455.
- Vleugel MM, Bos R, van der GP, Greijer A, Shvarts E, Stel A.H.V, W.E. van der, P.J. van Diest. Lack of lymphangiogenesis during breast carcinogenesis. *J Clin Pathol.* 2004; 57:746-751.
- Van der Schaft DW, Pauwels P, Hulsmans S, Zimmermann M, van de Poll-Franse LV, Griffioen AW. Absence of lymphangiogenesis in ductal breast cancer at the primary tumor site. *Cancer Lett.* 2007;254:128-136.
- Adams RH, Alitalo K. Molecular regulation of angiogenesis and lymphangiogenesis. *Nat Rev Mol Cell Biol.* 2007; 8:464-478.
- Maruyama K, Ii M, Cursiefen C, Jackson H, Keino DG, Tomita M, Van Rooijen N, Takenaka H, D'Amore PA, Stein-Streilein J, Losordo DW, Streilein JW. Inflammation-induced lymphangiogenesis in the cornea arises from CD11b-positive macrophages. *J Clin Invest.* 2005; 115:2363-2372.
- Mohammed RA, Ellis IO, Elsheikh S, Paish EC, Martin SG. Lymphatic and angiogenic characteristics in breast cancer: morphometric analysis and prognostic implications. *Breast Cancer Res Treat.* 2008;261-273.
- Van den Eynden GG, van der Auwera I, van Laere SJ, Trinh XB, Colpaert CG, van Dam P, Dirix LY, Vermeulen PB, Van Marck EA. Comparison of molecular determinants of angiogenesis and lymphangiogenesis in lymph node metastases and in primary tumours of patients with breast cancer. *J Pathol* 2007;213:56-64.
- Van der Auwera I, Van den Eynden GG, Colpaert CG, Van Laere SJ, van Dam P, Van Marck EA, Dirix LY, Vermeulen PB. Tumor lymphangiogenesis in inflammatory breast carcinoma: a histomorphometric study. *Clin. Cancer Res.* 2005;11:7637-7642.
- Van den Eynden GG, van der Auwera I, Van Laere S.J, et al. Comparison of molecular determinants of angiogenesis and lymphangiogenesis in lymph node metastases and in primary tumours of patients with breast cancer. *J Pathol.* 2007; 213: 56-64.
- Van den Eynden GG, Vandenbergh MK, van Dam PJ, Colpaert CG, van Dam P, . Dirix LY, Vermeulen PB, Van Marck EA. Increased sentinel lymph node lymphangiogenesis is associated with nonsentinel axillary lymph node involvement in breast cancer patients with a positive sentinel node. *Clin Cancer Res.* 2007;13:5391-5397.
- Van den Eynden GG, van der Auwera I, Van Laere SJ, Huygelen V, Colpaert CG, van Dam P, Dirix LY, Vermeulen PB, Van Marck EA. Induction of lymphangiogenesis in and around axillary lymph node metastases of patients with breast cancer. *Br J Cancer.* 2006;95:1362-1366.
- Ran S, Volk L, Hall K, Flister M.J, Lymphangiogenesis and lymphatic metastasis in breast cancer. *Pathophysiology.* 2010;17:229-251.
- Sullivan CA, Ghosh S, Ocal IT, et al. Microvessel area using automated image analysis is reproducible and is associated with prognosis in breast cancer. *Hum Pathol.* 2009;40:156-65.
- Dhakal HP, Bassarova A, Naume B, et al. Breast carcinoma vascularity: a comparison of manual microvessel count and Chalkley count. *Histol Histopathol.* 2009;24:1049-59.
- Dadras SS, Paul T, Bertoncini J, et al. Tumor lymphangiogenesis: a novel prognostic indicator for cutaneous melanoma metastasis and survival. *Am J Pathol.* 2003;162:1951-1960.

- (28) Trojan L, Michel MS, Rensch F, et al. Lymph and blood vessel architecture in benign and malignant prostatic tissue: lack of lymphangiogenesis in prostate carcinoma assessed with novel lymphatic marker lymphatic vessel endothelial hyaluronan receptor (LYVE-1). *J Urol.* 2004; 172:103–107.
- (29) Kannngum S, Thongsuksai P, Chewatanakornkul S, Chalkley Microvessel but not Lymphatic Vessel Density Correlates with Axillary Lymph Node Metastasis in Primary Breast Cancers. *Asian Pacific J Cancer Prev.* 2013;14(1):583-587
- (30) Neimiec J, Adamczyk A, Ambicka A, Mucha-Malecka A, Wysocki W, Mitus J, Rys R. Lymphangiogenesis assessment and its relation to tumour grade, breast cancer subtype and expression of basal markers. *Pol J Pathol.* 2012;3:165-171.