



# Assessment of lumbar spine disc degeneration in coherence to Pfirrmann Grades and Oswestry Disability Index

Suada Hasanović-Vučković<sup>1</sup>, Merim Jusufbegović<sup>1\*</sup>, Sandra Vegar-Zubović<sup>1</sup>, Lejla Milišić<sup>1</sup>, Adnan Šehić<sup>2</sup>, Ilvana Hasanbegović<sup>3</sup>, Adnan Beganović<sup>1</sup>

<sup>1</sup>Radiology Clinic, Clinical Center University of Sarajevo, Sarajevo, Bosnia and Herzegovina, <sup>2</sup>Department of radiological technologies, Faculty of Health Studies, University of Sarajevo, Sarajevo, Bosnia and Herzegovina, <sup>3</sup>Department of Anatomy, Faculty of Medicine, University of Sarajevo, Sarajevo, Bosnia and Herzegovina

## ABSTRACT

**Introduction:** Intervertebral disc (IVD) degeneration (IDD) is one of the main causes of low back pain (LBP). Standardized diagnostic algorithms for adequate estimation and classification of changes of lumbar discs are mandatory before starting with therapy.

**Methods:** One hundred patients who were indicated for lumbar magnetic resonance imaging (MRI) were included in the study. Pfirrmann grading system was used for the determination of IDD, while the visual analog scale (VAS) is used for evaluation of the intensity of LBP. To quantification of disability for LBP, we used the Oswestry Disability Index (ODI).

**Result:** Results showed higher Pfirrmann grades II and III for L2/L3 and L3/L4 lumbar levels and lower scores at L4/L5 and L5/S1. The analysis also showed low scores at the L2/3 and L3/4 lumbar level for Pfirrmann grades IV and V, and there was an increased at more inferior lumbosacral levels L4/5 and L5/S1. There was a significant correlation between Pfirrmann grades and ODI ( $p = 0.24$ ) as well as VAS ( $p = 0.16$ ).

**Conclusion:** Higher Pfirrmann grades correlated with increased ODI and VAS. Therefore, MRI can be used as a strong indicator of clinical appearance, but it is important to take into consideration that LBP should be correlated with clinical features. By summing Pfirrmann grades of all lumbar intervertebral levels in each patient, we can get more accurate insight for the status of the lumbar spine.

**Keywords:** Magnetic resonance; lumbar spine; low back pain; disc degeneration; Oswestry Disability Index; Pfirrmann disc grade; visual analog scale

## INTRODUCTION

During their lifetime, 80% of adults suffer from low back pain (LBP), and it represents the most

disabling condition worldwide (1). One of the most significant causes of LBP is intervertebral disc (IVD) degeneration (IDD). The IVD primary function is the transfer of weight that arises from body weight and muscle activity through the vertebral column (2). Alterations in the architectonics and biochemical structure of the disc transform the capability of the discs to carry load and result in disc degeneration. Because IDD and other disorders

\*Corresponding author: Merim Jusufbegović, Radiology Clinic, Clinical Center of Sarajevo University, Bolnička 25, 71000 Sarajevo, Bosnia and Herzegovina. E-mail: [mjusufbegovic@gmail.com](mailto:mjusufbegovic@gmail.com)

Submitted: 25 August 2020/Accepted: 10 October 2020

DOI: <https://doi.org/10.17532/jhsci.2020.1064>



have a high impact on imaging modalities and health-care system, standardized diagnostic algorithms for adequate estimation and classification of those degenerative changes of lumbar discs are mandatory before therapy. A most important method for the clinical assessment of intervertebral pathology is magnetic resonance imaging (MRI). Characteristics of the disc signal in T2-weighted MRI images reflect changes caused by aging or degeneration (3-5).

Pfarrmann et al. proposed an MRI-based 5-point scale for the grading of IDD which is based on MRI signal intensity disc structure, the distinction between nucleus and annulus and disc height on T2-weighted mid-sagittal images (6). It is important to differentiate Grades IV and V because disc height is not a feature that makes a difference for the distinction of Grades I to IV. At T2-weighted mid-sagittal fast spin-echo images, the homogeneity and the characteristics between nucleus and annulus being assessed (Grade I – Grade IV). Furthermore, Grade III and Grade IV may show a minor reduction of the disc height, while, in Grade V, the lumbar disc is collapsed.

Visual analog scale (VAS) is usually used for evaluation of the intensity of LBP. Even though there are many pain scales available, VAS is very often used due to reliability and validity, which is well established (7,8). VAS pain estimation relies on an acknowledgment of measures designed to quantify an aspect of pain. It should be taken into consideration that the intensity of pain is very subjective. Due to that, it is challenging to quantitatively assess the intensity of pain only using VAS.

The Oswestry Disability Index (ODI) is one of the most often used outcome measures for quantification of disability for the LBP (9). The patient questionnaire consists of ten questions regarding the patient's capability to cope with everyday life. The ODI can be independently applied and takes 5 minutes to complete. Because it can be easily administered, scored, and interpreted, ODI provides an important tool in clinical practice.

The purpose of this study is to evaluate the correlation between Pfarrmann grades of IDD and two commonly used systems of pain intensity (VAS) and condition-specific measures for the estimation of outcomes in spinal pathologies (ODI).

## METHODS

### Study participants

In this study, we included 100 patients who had scanned lumbar MRI. Every patient included in the study had a previous history of LBP without a history of spinal surgery. Patients who had scoliosis and evidence of vertebral fractures were also excluded from the study. The indications for the MRI were suspected disc herniation and LBP.

### Imaging technique

All MR images of the lumbar spine were performed on a 1.5T MRI unit (Vantage Titan 1.5T, Canon Medical Systems, Otawara, Tochigi, Japan) in the Clinical Center University of Sarajevo. Routinely, imaging protocol includes sagittal T1-weighted fast spin-echo images (TR 502 TE 9.7) with the following parameters: Matrix 512, field of view 250 mm, slice thickness 3.5 mm, interslice gap 10%, number of excitations 1; axial T2-weighted fast spin-echo images (TR 3530 TE 96) with the following parameters: Matrix 512, field of view 250 mm, slice thickness 3.5 mm, interslice gap 10%, number of excitations 1.

### Imaging evaluation

All MR images were analyzed on post-processing workstation (IMPAX 6.5.2.114 2011, Agfa HealthCare N.V., Morsel, Belgium) by a radiologist with over 5 years of experience in musculoskeletal imaging. Concerning the higher frequency and earlier occurrence of lumbar degenerative changes in the four motion segments, the readers were asked to grade the lumbar discs at lumbar levels L2/3, L3/4, L4/5, and L5/S1, respectively. In total, 400 lumbar discs were graded.

### ODI

ODI was used for the assessment of functional status. Before the examination, the supervising radiologist filled out a standardized questionnaire together with the patient. Between the questions regarding the intensity of pain, ability to stand, ability to care for oneself, the ability of lifting, ability to sit, ability to walk, sleep quality, social life, and ability to travel were prompted. The ODI is scored from 0 to 100%

and is interpreted as follows: 0–20%, minimal disability; 21–40%, moderate disability; 41–60%, severe disability; 61–80%, crippled; and 81–100%, bed-bound patients.

**Statistical analysis**

Statistical analysis was carried out using a commercially available software package (IBM SPSS Statistics V23.0). For statistical analysis, we used that the Pearson correlation test was used for evaluation of the linear relationship between two continuous variables evaluation of the monotonic relationship between two continuous or ordinal variables, which was made using the Spearman correlation test. Student’s t-test was used for testing a hypothesis based on a difference between sample means. Analysis of group data was made by the nonparametric Kruskal–Wallis test. In all statistical analyses,  $p < 0.05$  was considered significant.

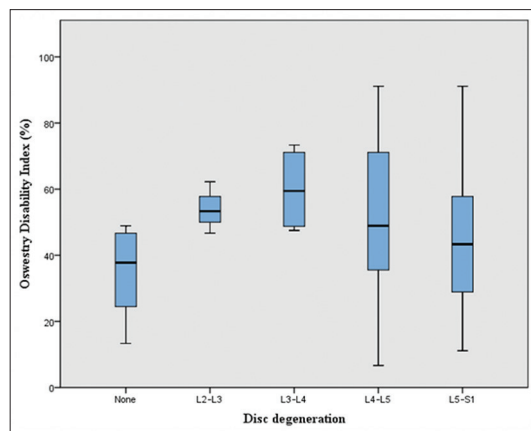
**RESULTS**

In this study, we included 100 patients, 35 males, and 65 females with a mean age of 47, 6 years. Overall, 400 lumbar discs at levels L2/3, L3/4, L4/5, and L5/S1 were analyzed in 100 patients. The frequency of Pfirrmann grades I was low at the L2/3 (0.5%) and L3/4 (0.25 %) vertebral level. There was no Pfirrmann grade I change at level L4/5 and L5/S1. Pfirrmann grade II changes were higher at superior lumbar levels (L2/3 6% and L3/4 4.25%) than inferior lumbar levels (L4/5 2.25% and L5/S1 1.75%) Pfirrmann grade III changes were higher at superior lumbar levels (L2/3 14.75% and L3/4 12%) than inferior lumbar levels (L4/5 4.5% and L5/S1 6.25%). Pfirrmann grade IV were lower at the L2/3 (3.25%) and L3/4 (7.75 %), but increased at more inferior lumbosacral levels (L4/5 14.75% and L5/S1 10.75%). As well as Pfirrmann grade IV

and Pfirrmann grade V showed lower scores at the L2/3 (0.5%) and L3/4 (0.75 %), but increased at more inferior lumbosacral levels (L4/5 3.5% and L5/S1 6.25%). The Pfirrmann grading of IVDs is shown in Table 1.

Graph 1 shows a significant correlation between the level of IDD and ODI ( $p = 0.022$ ). There is a significant correlation between Pfirrmann grade and VAS ( $p = 0.001$ ) and ODI ( $p = 0.043$ ). Patients who had higher Pfirrmann grades had lower life quality and felt greater pain. Pfirrmann grades were also summed for all analyzed disc in each patient included in the study. Those Pfirrmann scores were correlated to ODI and VAS, and results showed a significant correlation between VAS ( $p = 0.16$ ) as well as ODI ( $p < 0.24$ ).

In terms of the ODI scores, patient’s disability had a minimum of 7% and a maximum of 91% with an arithmetic mean of  $48.38 \pm 18.76\%$ . There was a statistical difference between the grade of disability in men ( $41.97 \pm 19.18\%$ ) and women



**GRAPH 1.** Box plot of the ODI and Pfirman grades in the present study showing a significant correlation (Spearman’s  $\rho$ -test,  $p = 0.022$ ).

**TABLE 1.** Pfirrmann grades of disc degeneration for levels L2/3, L3/4, L4/5 and L5/S1 (number od discs)

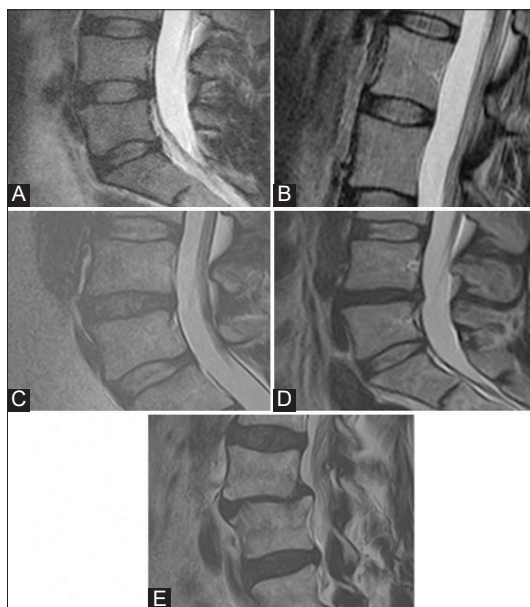
Lumbar level		Pfirman classification					Total
		I	II	III	IV	V	
L2/3	n (%)	2 (2)	24 (24)	59 (59)	13 (13)	2 (2)	100
L3/4	n (%)	1 (1)	17 (17)	48 (48)	31 (31)	3 (3)	100
L4/5	n (%)	0	9 (9)	18 (18)	59 (59)	14 (14)	100
L5/S1	n (%)	0	7 (7)	25 (25)	43 (43)	25 (25)	100
Total	n (%)	3 (0.75)	57 (14.25)	150 (37.5)	146 (36.5)	44 (11)	400

(51.88 ± 17.62%). The largest group of patients (37.4%) had severe disability (41–60%).

## DISCUSSION

LBP represents a frequent musculoskeletal disorder in all age groups around the world. Occurring prevalence is between 25% and 60% making it a frequent reason for activity restriction in people younger than 50 years. Besides, more than 85% of all people have LBP at some time in their life (9-11). A large number of patients with LBP, despite imaging modalities such as MRI, remains without a specific diagnosis (12). Because almost all lumbar structures are plausible sources of LBP, it may serve as a possible cause (13,14). One of the main causes of LBP is IDD of the lumbar spine (15,16). The IVD is a compound of a fibrocartilaginous structure made up of three distinct components. Those are the nucleus pulposus, the annulus fibrosus, and the cartilaginous endplates. If any integrity of those three structures is disturbed that it may result in a compromised function of the whole IVD which undergoes dynamic morphologic and cellular alterations with age and degeneration (17). Although the etiology is not fully described, it is considered that being overweight, frequent oscillations during driving, heavy physical loading, and driving have a great association with IDD (18-22). Studies have shown that by the age of 50 years, 85–95% of adults show evidence of degenerative disc disease postmortem (17). Because radiological features of IDD are universal, it generally remains uncertain to what extent these changes are accountable for the clinical symptoms of the patient. Taking into consideration the need for standardized nomenclature in the evaluation of IVD, Stelzeneder et al. introduced T2 mapping as a method (6). Pfirrmann et al. suggested a morphologic grading system which is based on T2-weighted sagittal images (Figure 1) that showed a good interobserver accuracy (6).

An analysis of the Pfirrmann grading revealed the prevalence of grades in the following percentages: I (0.75%), II (14.25%) III (37.5%), IV (36.5%), and Grade V discs (11%). These research discoveries suggest that our patients had more serious degeneration of lumbar discs in comparison with those reported in other studies (23-25). For all patients, we summarized all grades and correlated them with



**FIGURE 1.** Pfirrmann divided into Grades I (A), II (B), III (C), IV (D), and V (E).

ODI and VAS test revealed a significant correlation in the Pfirrmann grades, VAS ( $p = 0.16$ ), and ODI ( $p = 0.24$ ). So far, there is no study done in which the grades for all levels of the lumbar spine were summed up and used as one grade, final grade. By summing grades, we can get a clearer and better assessment of the condition of the lumbar spine. This shows that the thesis has been confirmed with the correlation between ODI and VAS.

A large number of patients presented in our study revealed a higher number of lumbar discs with Pfirrmann grades III and IV changes (14.25%, 37.5%, and 36.5%) in comparison to lumbar discs with Pfirrmann grades II and V (14.25% and 11%). Only 0.75% showed no degenerative changes in lumbar discs. This data clarify the difficulty to rate the clinical symptoms accurately based only on imaging findings. All structures are a possible cause of pain in the lower back, and therefore, it is necessary to consider everything. For that reason, we correlated IDD changes with ODI and VAS in this study. The results showed a strong correlation between signs of degeneration and ODI and VAS.

A limitation of the study was the number and age of study participants because Pfirrmann grade V

has difficulty distinguishing lumbar disc pathology in the elderly spine (mean age 47.5 years; range 17.7–67.4 years). We have to take into consideration that pain represents subjective experience, and it is affected by emotional, pathological, genetic, and cognitive elements. It is an accepted opinion that chronic LBP is a several factor disorder and cannot be circumscribed with one lumbar compartment.

## CONCLUSION

IDD of the lumbar spine is accurately detected on MRI. The Pfirrmann grading system can easily be formed. By summarizing Pfirrmann grades for each intervertebral level, we can get a more accurate insight into the condition of the lumbar spine. These findings are backing statement that clinical findings are adjunct and requests for adequate clinical approach with patients who have LBP. Further, investigation on a larger population sample is needed.

## REFERENCES

- Deyo RA, Weinstein JN. Low back pain. *N Engl J Med* 2001;344(5):363-70. <https://doi.org/10.1056/nejm200102013440508>.
- Urban JP, Roberts S. Degeneration of the intervertebral disc. *Arthritis Res Ther* 2003;5(3):120-30.
- Oh C, Yoon S. Whole spine disc degeneration survey according to the ages and sex using pfirrmann disc degeneration grades. *Korean J Spine* 2017;14(4):148-54. <https://doi.org/10.14245/kjs.2017.14.4.148>.
- Kalichman L, Carmeli E, Been E. The association between imaging parameters of the paraspinal muscles, spinal degeneration, and low back pain. *Biomed Res Int* 2017;2017:1-14. <https://doi.org/10.1155/2017/2562957>.
- Iriondo C, Padoia V, Majumdar S. Lumbar intervertebral disc characterization through quantitative MRI analysis: An automatic voxel based relaxometry approach. *Magn Reson Med* 2020;84(3):1376-90. <https://doi.org/10.1002/mrm.28210>.
- Pfirrmann CW, Metzdorf A, Zanetti M, Hodler J, Boos N. 293 magnetic resonance classification of lumbar intervertebral 294 disc degeneration. *Spine* 2001;26(17):1873-8. <https://doi.org/10.1097/00007632-200109010-00011>.
- Chiarotto A, Maxwell L, Ostelo R, Boers M, Tugwell P, Terwee C. Measurement properties of visual analogue scale, numeric rating scale, and pain severity subscale of the brief pain inventory in patients with low back pain: A systematic review. *J Pain* 2019;20(3):245-63. <https://doi.org/10.1016/j.jpain.2018.07.009>.
- Melzack R, Katz J. Pain measurement in persons in pain. In: Wall PD, Melzack R, editors. *Textbook of Pain*. 4<sup>th</sup> ed. New York: Churchill Livingstone; 1999. p. 129-64. <https://doi.org/10.1016/b0-443-07287-6/50023-0>.
- Fairbank JC, Pynsent PB. The Oswestry disability index. *Spine* 2000;25(22):2940-52. <https://doi.org/10.1097/00007632-200011150-00017>.
- Buchbinder R, Blyth FM, March LM, Brooks P, Woolf AD, Hoy DG. Placing the global burden of low back pain in context. *Best Pract Res Clin Rheumatol* 2013;27(5):575-89. <https://doi.org/10.1016/j.berh.2009.11.002>.
- Hoy D, March L, Brooks P, Woolf A, Blyth F, Vos T, et al. Measuring the global burden of low back pain. *Best Pract Res Clin Rheumatol* 2010;24(2):155-65. <https://doi.org/10.1016/j.berh.2009.11.002>.
- Van der Windt DA, Dunn KM. Low back pain research-future directions. *Best Pract Res Clin Rheumatol* 2013;27(5):699-708. <https://doi.org/10.1016/j.berh.2013.11.001>.
- Spletstößer A, Khan M, Zimmermann B, Vogl T, Ackermann H, Middendorp M, et al. Correlation of lumbar lateral recess stenosis in magnetic resonance imaging and clinical symptoms. *World J Radiol* 2017;9(5):223. <https://doi.org/10.4329/wjr.v9.i5.223>.
- Andersen JC. Is immediate imaging important in managing low back pain? *J Athl Train* 2011;46(1):99-102. <https://doi.org/10.4085/1062-6050-46.1.99>.
- Chou D, Samartzis D, Bellabarba C, Patel A, Luk KD, Kisser JM, et al. Degenerative magnetic resonance imaging changes in patients with chronic low back pain: A systematic review. *Spine* 2011;36(21):S43-53. <https://doi.org/10.1097/brs.0b013e31822ef700>.
- Cheung KM, Samartzis D, Karpainen J, Luk KD. Are "patterns" of lumbar disc degeneration associated with low back pain? New insights based on skipped level disc pathology. *Spine* 2012;37(7):E430-8. <https://doi.org/10.1097/brs.0b013e3182304dfc>.
- Takatalo J, Karpainen J, Niinimäki J, Taimela S, Nayha S, Mutanen P, et al. Does lumbar disc degeneration on magnetic resonance imaging associate with low back symptom severity in young Finnish adults? *Spine* 2011;36(25):2180-9. <https://doi.org/10.1097/brs.0b013e3182077122>.
- Hangai M, Kaneoka K, Kuno S, Hinotsu S, Sakane M, Mamizuka N, et al. Factors associated with lumbar intervertebral disc degeneration in the elderly. *Spine J* 2008;8(5):732-40. <https://doi.org/10.1016/j.spinee.2007.07.392>.
- Samartzis D, Karpainen J, Chan D, Luk KD, Cheung KM. The association of lumbar intervertebral disc degeneration on magnetic resonance imaging with body mass index in overweight and obese adults: A population-based study. *Arthritis Rheum* 2012;64(5):1488-96. <https://doi.org/10.1002/art.33462>.
- Takatalo J, Karpainen J, Taimela S, Niinimäki J, Laitinen J, Sequeiros RB, et al. Body mass index is associated with lumbar disc degeneration in young Finnish males: Subsample of Northern Finland birth cohort study 1986. *BMC Musculoskelet Disord* 2013;14:87. <https://doi.org/10.1186/1471-2474-14-87>.
- Takatalo J, Karpainen J, Taimela S, Niinimäki J, Laitinen J, Sequeiros RB, et al. Association of abdominal obesity with lumbar disc degeneration-a magnetic resonance imaging study. *PLoS One* 2013;8(2):e56244. <https://doi.org/10.1371/journal.pone.0056244>.
- Papic M, Papic V, Kresoja M, Munteanu V, Mikov I, Cigic T. Relation between grades of intervertebral disc degeneration and occupational activities of patients with lumbar disc herniation. *Vojnosanit Pregl* 2017;74(12):1121-7. <https://doi.org/10.2298/vsp151112306p>.
- Marshman L, Trehwella M, Friesem T, Bhatia C, Krishna M. Reverse transformation of modic Type 2 changes to modic Type 1 changes during sustained chronic low-back pain severity. *J Neurosurg Spine* 2007;6(2):152-5. <https://doi.org/10.3171/spi.2007.6.2.152>.
- Jensen T, Kjaer P, Korsholm L, Bendix T, Sorensen J, Manniche C, et al. Predictors of new vertebral endplate signal (modic) changes in the general population. *Eur Spine J* 2009;19(1):129-35. <https://doi.org/10.1007/s00586-009-1184-5>.
- Feng Z, Liu Y, Yang G, Battié M, Wang Y. Lumbar vertebral endplate defects on magnetic resonance images. *Spine* 2018;43(13):919-27. <https://doi.org/10.1097/brs.0000000000002450>.