



Incidence of impacted mandibular third molars in population of Bosnia and Herzegovina: a retrospective radiographic study

Sadeta Šečić^{1*}, Samir Prohić¹, Sanja Komšić¹, Amra Vuković²

¹Department of Oral Surgery, Faculty of Dentistry, University of Sarajevo. ²Department of Preclinical Dentistry, Faculty of Dentistry, University of Sarajevo

ABSTRACT

Introduction: Impaction may be defined as the failure of complete eruption into a normal functional position of one tooth within normal time due to lack of space in the dental arch, caused by obstruction by another tooth or development in an abnormal position. The mandibular third molar is the most frequently impacted tooth. The incidence varies from 9.5% to 68% in different populations.

Methods: The study was conducted in Department of Oral Surgery, Faculty of Dentistry, University in Sarajevo. Study represents retrospective analysis of panoramic radiographs (orthopantomograms) of patients referred to Department of Oral Surgery from January 2010 to February 2013 with indication for surgical removal of impacted third molars.

Results: Of the 2000 radiographs, 761 presented with at least one impacted third molar (38%). A total of 1034 impacted mandibular third molars were present (51.7%). The most common age group was third decade (61.2%). Significant statistical difference in incidence of third molar impaction was found between females and males ($p < 0.05$), but there was no statistical difference in incidence in urban and suburban population ($p = 0.374$). Vertical angulation was the most common pattern of impaction (65%). Frequency of third molars erupted into their normal position (class IA) was 42%. Impacted mandibular molars were associated with periodontal pockets in 134 (6.5%) cases and with dentigerous cysts in 5 cases (0.2%).

Conclusion: The present study provides useful data regarding the clinical status of third molars in population of Bosnia and Herzegovina.

Keywords: impacted mandibular third molars, incidence, Bosnia and Herzegovina

INTRODUCTION

Impaction may be defined as the failure of complete

eruption into a normal functional position of one tooth within normal time due to lack of space in the dental arch, caused by obstruction by another tooth or development in an abnormal position (1). The most often congenitally missing as well as impacted teeth are the third molars, which are present in 90% of the population with 33% having at least one impacted third molar (2). They account for 98% of all the impacted teeth (3). The mandibular third molar

*Corresponding author: Sadeta Šečić, DDS, PhD
Department of Oral Surgery; Faculty of Dentistry
University of Sarajevo; Bolnička 4a, 71000 Sarajevo;
Bosnia and Herzegovina
E-mail: sadetas@gnet.ba

Submitted 14 March 2013 / Accepted 3 June 2013



is the most frequently impacted tooth (4). The incidence varies from 9.5% to 68% in different populations (5-8).

Several factors have been reported to be responsible for the high rate of impaction of mandibular third molars. These include deficient space in the dental arch (9), unfavourable angulations and aberrant path of eruption, density of overlying soft and hard tissues, and the late eruption sequence (4). Mesiodistal width of the third molar may also play a role in the tendency for impactions. Svendsen and Maertens have reviewed in detail the etiology of third molar impactions. Two of the cited causes are:

1. lack of space: insufficient anterior-posterior dimension, transverse distance of the alveolar process in the third molar region. Wide alveolar shelves and a greater mandibular width at the ramus in relation to the intermolar width is important for successful eruption of the third molars.
2. Late third molar mineralization and early physical maturation (10).

Some of the pertinent causes of insufficient anterior-posterior space are tooth jaw size discrepancy from evolutionary changes, and insufficient sagittal growth of the mandible as continuous elongation of the third molar region between 8 and 20 years of the age is necessary. According to Richardson, this elongation provides for forward movement of the first molar, together with ramus resorption to provide third molar space for eruption (11). Although third molar impaction has multifactorial elements, inadequate retromolar space for eruption is considered to be the major factor (12,13).

Most studies have reported no sexual predilection in third molar impaction (8,13,14). Some studies, however, have reported a higher frequency in females than males (8,15): in white European females (15,16) and Singapore Chinese females than males (8). Impacted teeth are often associated with pericoronitis, periodontitis, cystic lesions, neoplasm, root resorption and can cause detrimental effects on adjacent tooth (17).

Several methods have been used to classify impaction, in which impaction is described based on the level of impaction (18), the angulations of the third molars (19), and the relationship to the anterior border of the ramus of the mandible (18). Winter's (19)

and Pell and Gregory (18) classifications are most commonly used to classify impacted mandibular third molars. In Winter's classification, the angulation of impaction of the mandibular third molar is determined by the angle formed between the intersected longitudinal axes of mandibular second and third molars (19). Level (depth) of impaction can be classified using the Pell and Gregory classification system, where the impacted teeth are assessed according to their relationship to the occlusal surface of the adjacent second molar, and their position according to anterior border of the ramus of the mandible (10).

The aim of our study was to evaluate the incidence and the pattern of impaction of mandibular third molars in population of Bosnia and Herzegovina using panoramic radiographs of patients referred to Department of Oral Surgery Faculty of Dentistry, University in Sarajevo.

METHODS

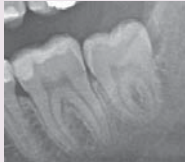



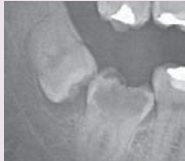

Study sample

The study was conducted in Department of Oral Surgery, Faculty of Dentistry, University in Sarajevo. Study represents retrospective analysis of panoramic radiographs (orthopantomograms) of patients referred to Department of Oral Surgery from January 2010 to February 2013 with indication for surgical removal of impacted third molars. Upon giving necessary information to patients regarding medical procedure, the patients signed the consent. Two thousand radiographs were reviewed and related data were selected from their dental records. Data were entered in data base specially designed for this study. Inclusion criteria of the study group was complete root formation of mandibular third molar. Exclusion criteria were: patients younger than 19 years, poor quality of OPG, incomplete records, presence of dentoalveolar trauma or other pathological dentoalveolar condition, presence of any systemic or craniofacial anomaly or syndrome (such as Down syndrome, cleidocranial dysostosis) and absence of mandibular second molar.

Radiography analysis

To eliminate the inter-examiner errors, the radiographs were analyzed by a single examiner in a dark

TABLE 1. Winter's classification of impacted mandibular third molars

Impaction pattern	Angulation (angle formed between the intersected longitudinal axes of the second and third molars)	Radiograph showing impaction pattern
Vertical impaction	10° to -10°	
Mesioangular impaction	11° to 79°	
Horizontal impaction	80° to 100°	
Distoangular impaction	-11° to -79°	
Other impactions	111° to -80°	
Buccolingual impaction	any tooth oriented in a buccolingual direction with crown overlapping the roots	

room using an appropriate X-ray viewer and magnifying lenses. The angulation and class and type pattern of impaction were established via visual impression. The radiographs were interpreted for the following:

1. Presence of impacted mandibular molars. Third molar was considered impacted if it was not in functional occlusion and at the same time, its roots were fully formed.
2. Angulation pattern of impacted mandibular

molars. The angulation of impacted third molar was documented based on Winter's classification with reference to the angle formed between the intersected longitudinal axes of the second and third molars: the vertical impaction (10° to -10°), mesioangular impaction (11° to 79°), horizontal impaction (80° to 100°), distoangular impaction (-11° to -79°), others (111° to -80°) and buccolingual impaction (any tooth oriented in a buccolingual direction with crown overlapping the roots) (table 1).

Table 1 shows the angulation of impacted third molar based on Winter's classification with reference to the angle formed between the intersected longitudinal axes of the second and third molars.

3. Class and type pattern of impacted mandibular molars. The level of eruption was documented according to the classification of Pell and Gregory as follows:

Class I: The crown of the impacted mandibular third molar is completely anterior to the anterior border of the ramus of the mandible.

Class II: Approximately one half of the crown is covered by the ramus

Class III: The impacted mandibular third molar is located completely within the mandibular ramus.

Position A: Occlusal surface of the impacted mandibular third molar is level or nearly level with the occlusal plane of the second molar.

Position B: Occlusal surface of the impacted mandibular third molar is between the occlusal plane and cervical line of the second molar.

Position C: Occlusal surface of the impacted mandibular third molar is below the cervical line of the second molar.

Statistical analysis

The data were recorded into specially designed forms containing the following information: age, gender, place of residence, region, impacted tooth, angulation of impaction (according to Winter's classification), level of impaction (according to Pell and Gregory classification), pathology and complications associated with impacted and semi-impacted third molars. To facilitate the analysis and presentation of data in tables, numerical codes were assigned for each variable. Data were analyzed using Statistical package for Social Sciences SPSS (SPSS Inc, Chicago, USA) version 20.0. An unpaired t-test was used for the statistical analysis at significance level of $P < 0.05$ to compare variables between groups. All data regarding patient identification and medical history were kept confidential.

RESULTS

Of the 2000 radiographs, 761 presented with at least one impacted third molar (38%). A total of

1034 impacted mandibular molars were present: 508 (24.5%) mandibular left third molar (38) and 526 (25.4%) mandibular right third molar (48). Of the 761 patients, 270 (36%) were male and 491 (64%) female. The male to female ratio was 1:1.8. The age range was from 19 to 85 years with mean age \pm standard deviation = 27 ± 9 . The most common age group was third decade (61.2%) followed by the fourth (19.3%). Significant difference in incidence of impaction was found between females and males ($p < 0.05$). There was no statistical significance in prevalence of impacted third molars in urban and suburban population ($p = 0.374$). Impacted mandibular third molars were predominantly associated with impacted maxillary third molars: bilateral maxillary and mandibular impaction of third molars were present in 139 (23.5%) cases. Unilateral impacted mandibular third molars were present in 116 (19.6%) cases and bilateral impacted mandibular third molars in 92 cases (15.6%).

Vertical angulation was the most common pattern of impaction (65%), followed by mesioangular (20%), horizontal (9%), distoangular (5%) and buccolingual (1%). Other angulation (inverted) was present in less than 1% of cases (table 2, figure 1). The occurrence of different pattern of angulation of impacted mandibular third molars in males and females shows statistical significance ($p < 0.05$).

The occurrence of different level of impaction is shown in table 2. Majority of patients presented with class I (59%), followed by class II (29%) and class III (12%). Frequency of third molars erupted into their normal position (class IA) was 42%. Most common pattern of impaction is IIB (13.6%), IIA (11.7%), IB (10.7%) and IIIC (10.2%). Rarest patterns are IIIA (0.8%) and IIIB (0.7%).

The most common pathology associated with impacted third molars is dental caries in the second or third molar (figure 2) which was recorded in 174 cases (17% of cases). Impacted mandibular third molars were associated with periodontal pockets (figure 3) in 134 (13%) cases, dentigerous cysts (figure 4) in 5 cases (0.5%) and root resorption of second molar (figure 5) in 2 cases (0.2%). Majority of periodontal pockets were present in impacted molars with vertical angulation (81%) and Class II of level of impaction (52%), which was statistically significant ($p < 0.05$).

TABLE 2. Angulation pattern of mandibular third molars based on Winter's classification).

	ANGULATION PATTERN OF MANDIBULAR THIRD MOLARS												Total
	Vertical angulation		Mesioangular angulation		Horizontal angulation		Distoangular angulation		Other angulations		Bucolingual angulation		
	Fre- quency	Percent- age	Fre- quency	Percent- age	Fre- quency	Percent- age	Fre- quency	Percent- age	Fre- quency	Percent- age	Fre- quency	Percent- age	
Mandibular left molar (38)	318	31%	116	11%	45	4%	23	2%	2	0.40%	4	0.80%	508
Mandibular right molar (48)	355	34%	90	9%	47	5%	31	3%	2	0.40%	1	0.20%	526
Total	673	65%	206	20%	92	9%	54	5%	4	0.80%	5	1%	

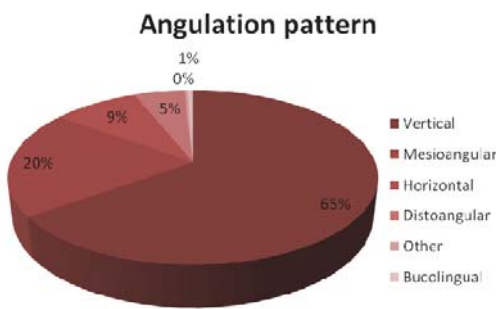


FIGURE 1. Angulation pattern of impacted mandibular third molars (based on Winter's classification).

TABLE 3. Level pattern of mandibular third molars according to the classification of Pell and Gregory.

LEVEL PATTERN OF MANDIBULAR THIRD MOLARS (PELL & GREGORY CLASSIFICATION)				
	Frequency	Percent- age	Frequency (Total)	Percent- age (Total)
Class I Position A	437	41.9	620	59.6
Class I Position B	112	10.7		
Class I Position C	71	7.0		
Class II Position A	122	11.7	299	28.7
Class II Position B	142	13.6		
Class II Position C	35	3.4		
Class III Position A	9	0.8	122	11.7
Class III Position B	7	0.7		
Class III Position C	106	10.2		

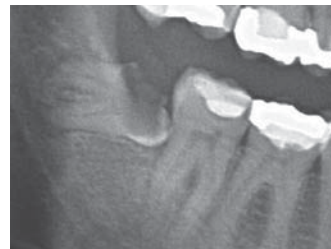

FIGURE 2. Pathology associated with impacted mandibular third molars: radiograph of dental caries in semi-impacted mandibular third molar.

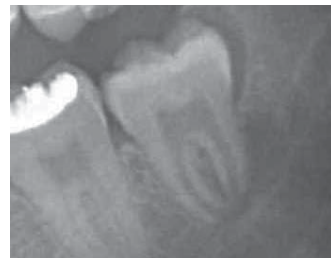


FIGURE 3. Pathology associated with semi-impacted mandibular third molars: Radiograph of periodontal pocket at the distal aspect of mandibular third molar.

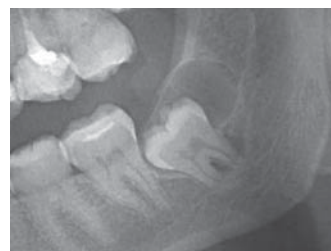

FIGURE 4. Pathology associated with impacted mandibular third molars: Radiograph of dentigerous cyst arising around impacted mandibular third molar.

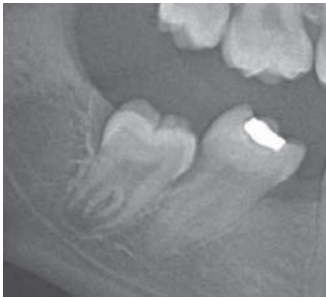


FIGURE 5. Pathology associated with impacted mandibular third molars: radiograph of root resorption of second mandibular molar as result of semi-impacted third molar.

DISCUSSION

This is the first study to evaluate incidence of impacted third mandibular molars in population of Bosnia and Herzegovina. According to Institute for Public Health of Federation of Bosnia and Herzegovina, there is no data regarding incidence of impacted teeth in population of Bosnia and Herzegovina (20). Also, there is no conducted and published researches from other institutions in Bosnia and Herzegovina which deal with impacted teeth. The sample size used was equivalent to the samples used in many other international studies (7,8,21,22), and selection of patients was also like other studies which enables comparison of results. Since study sample consists of all patients referred to Department of Oral Surgery from ten Cantons of the Federation of Bosnia and Herzegovina, study sample represents population of the Federation of Bosnia and Herzegovina. The predominant age group in our study is third decade, which is in agreement with results of other authors (17,23,24,25). This may be related to early removal of impacted third molars due to prophylactic indication in orthodontic patients and increasing awareness about oral health. Many studies reported gender predilection in third molar impactions (8,15,17,34). Results of our study are in agreement with previous reports, since there is statistical significance in distribution of impacted teeth between females and males ($p < 0.05$). The higher frequency reported in females is due to the consequence of difference between the growth of males and females. Females usually stop growing when the third molars just begin to erupt, whereas in males, the growth of the jaws continues during the time of eruption of the third molars, creating

more space for third molar eruption (9). The frequency of patients with at least one impacted third molar in our study is 38%, which is in accordance with findings of other authors: Hassan (40%) (21), Rajasuo et al (38%) (22), Hattab (33%) (6) and Eliasson (30%) (27). Higher prevalence of impacted teeth was found in study of Morris and Jerman in a study conducted in USA on 5000 subjects (65%) (28), probably as a result of different age groups included in study since our study represents all age groups; and also in study of Quek et al. on 1000 subjects of Chinese population (68%) due to higher jaw teeth size discrepancy, wider teeth and smaller dental arch length of Chinese population compared with Caucasians (8). The frequency of normally erupted third molars in our study is 42%, which is lower than findings of other studies conducted on Afro-American population (58%) (29) and Indian population (65%) (30) which suggests racial and ethnic factors contributing to impaction of third molars. Olosoji reported impacted third molars are up to 7 times more common in the urban than rural areas in Nigeria and also, when it occurred, third molar impactions affected all the four third molars much more frequently in urban than in rural population. This suggests impaction of third molars is urban phenomenon since dental arch length of urban population is undergoing an unnoticed transition process of disuse atrophy. This is in accordance with many surveys which have shown that impactions and malocclusions attain high levels in industrialized countries of Europe and North America. In contrast, surveys carried out in communities with a simple mode of life have in general shown a lower incidence of dental irregularities (31). However, our study did not show statistically significant difference in prevalence of impaction in urban and suburban areas ($p > 0.05$). According to majority of the studies, the most common angulation of impaction is mesioangular (8,21,28,30,32,33). However, in our study the most common angulation of impaction is vertical (65%), which is in accordance with findings of Hugoson and Kugelberg in a study conducted on Swedish population (15). This again underlines the significance of racial and ethnic factors in pattern of third molar impactions, since study sample of our study and study of Hugoson was European Caucasian population. Differences may also be partly due to different method of classification of angulation that was used in studies. Level of impaction was as-

sessed according to the relationship of level of occlusal surface of third molar with adjacent second molar. The most common type of impaction regarding Pell and Gregory classification is IIB (13.6%) like reports of Almandros-Marques from Spain (34), following by IIA (11.7%) which is the most common type in Italian population (35). Consequently, the findings of this study are in agreement with large number of reports that show that most impacted third molars were at Class II position where half of the crown was in the ramus and the position of the highest portion of third molar was between the occlusal plane and cervical line of the second molar, which is position B. The Pell and Gregory and Winter classifications are used to document the position of the impacted mandibular third molars, but also these classifications can be used to predict the surgical difficulty and to evaluate the risk of postoperative complications. Most of the complications are associated with a greater degree of impaction and it seems that position of angulation has impact on postoperative complications (36). That why evaluation of pattern, type and class of impaction has also the clinical significance, not just the epidemiological.

CONCLUSION

The present study provides useful data regarding the clinical status of third molars in population of Bosnia and Herzegovina. 38% of patients presented with at least one impacted third molar. The most common age group was third decade. Significant difference in incidence of impaction was found between females and males, but there was no statistical significance in prevalence of impacted third molars in urban and suburban population. Vertical angulation was the most common pattern of impaction. Majority of patients presented with class I of level of impaction. The most common pathology associated with impacted third molars is dental caries in the second or third molar. Future studies should be conducted on randomized sample representative of all regions of Bosnia and Herzegovina. They are required to evaluate the etiology of impacted third molars in population of Bosnia and Herzegovina as well as linking epidemiological data with incidence of postoperative sequelae and complications associated with surgical removal of impacted mandibular molars.

REFERENCES

1. Khawaja NA. Third molar impaction: a review. *J Pak Dent Assoc* 2006;15:97-101.
2. Haq Z. A Survey of reasons for Surgical Removal of Impacted Mandibular third Molar in Armed Forces Personnel at AFID Rawalpindi. *Pak Oral Dent J* 2002;22:137-9.
3. Sademi Fayad J, Levy JC, Yazbeck C, Cavezian R, Cabanis EA. Eruption of third molars: relationship to inclination of adjacent molars. *Am J Orthod Dentofacial Orthop* 2004;125:200-2.
4. Peterson LJ. Principles of management of impacted teeth. In: Peterson LJ, Eills E, Huop JR, Tucker MR, editors. *Contemporary oral and maxillofacial surgery*. 4th ed. New York: Mosby; 2003:184-213.
5. Lima CJ, Silva LC, Melo MR, Santos JA, Santos TS. Evaluation of the agreement by examiners according to classifications of third molars. *Med Oral Patol Oral Cir Bucal*. 2012;17:281-216.
6. Hattab FN, Fahmy MS, Rawashedeh MA. Impaction status of third molars in Jordanian students. *Oral Surg Oral Med Oral Pathol Radiol Endod*. 1995;79(1):24-29.
7. Haidar Z, Shalhoub SY. The incidence of impacted wisdom teeth in a Saudi community. *Int J Oral Maxillofac Surg*. 1986;15(5):569-571.
8. Quek SL, Tay CK, Tay KH, Toh SL, Lim KC. Pattern of third molar impaction in a Singapore Chinese population: a retrospective radiographic survey. *Int J Oral Maxillofac Surg*. 2003;32(5):548-552.
9. Bishara SE, Andreasen G. Third molars: a review. *Am J Orthod* 1983;83:131-7.
10. Svendsen H, Maertens JKM. Etiology of third molar impaction. In: Andreasen JO, Petersen JK, Laskin DM, eds: *Textbook and Color Atlas of Tooth Impactions*. Copenhagen: Munksgaard 1997:223-227.
11. Richardson ME. Lower third molar space. *Angle Orthod* 1987;57:155-161.
12. Olive R, Basford K. Reliability and validity of lower third molar space assessment techniques. *Am J Orthod* 1981;79:45-53.
13. Niedzielska IA, Drugacz J, Kus N, Kreska J. Panoramic radiographic predictors of mandibular third molar eruption. *Oral Surg Oral Med Oral Pathol Oral Radiol Endod* 2006;102:154-8.
14. Kaya GS, Aslan M, Ömezli MM, Dayi E. Some morphological features related to mandibular third molar impaction. *J Clin Exp Dent*. 2010;2:12-7.
15. Hugoson A, Kugelberg CF. The prevalence of third molars in a Swedish population. An epidemiological study. *Community Dental Health*. 1988;5(2):121-138.
16. Murtomaa H, Turtola I, Ylipaavalniemi P, Rytomaa I. Status of the third molars in the 20- to 21-year-old Finnish university population. *J Am Coll Health*. 1985;34(3):127-129.
17. Maraita J, Alwrikat A. Is the mandibular third molar a risk factor for mandibular angle fracture? *Oral Surg Oral Med Oral Pathol Oral Radiol Endod*. 2000;89:143-6.
18. Pell GJ, Gregory BT. Impacted mandibular third molars: classification and modified techniques for removal. *Dent Digest*. 1933;39:330-338.
19. Winter GB. *The Principles of Exodontia as Applied to the Impacted Third Molar*. St. Louis, MO: American Medical Book Co; 1926.
20. Institute for Public Health Federation of Bosnia and Herzegovina. Health Condition of Population of Federation of Bosnia and Herzegovina and Health Care in Federation of Bosnia and Herzegovina in 2011. 2012 Jul [cited 2013 Jul 29]; 35-37. Available from: <http://www.zzzfbih.ba/wp-content/uploads/2009/02/Zdravstveno-stanje-stanovnis%CC%8Ctva-i-zdravstvena-zas%CC%8Ctita-u-FBIH-2011.pdf>
21. Hassan AH. Pattern of third molar impactions in a Saudi population. *Clinical, Cosmetic and Investigational Dentistry* 2010;2:109-113
22. Rajasuo A, Murtomaa H, Meurman JH. Comparison of the clinical status of third molars of young men in 1949 and in 1990. *Oral Surg Oral Med Oral Pathol*. 1993;76(6):694-698.
23. Osborn TP, Frederickson Jr G, Small IA, Torgerson TS. Prospective study of complications related to mandibular third molar surgery. *J Oral Maxillofac Surg* 1985; 43(10):767-9.

24. Ishfaq M, Wahid A, Rahim AU, Munim A. Patterns and presentations of impacted mandibular third molars subjected to removal at Khyber College of Dentistry Peshawar. *Pak Oral Dent J* 2006;26:221-6.
25. Ayaz H, Rehman A. Pattern of impacted mandibular third molar in patients reporting Department of Oral and Maxillofacial Surgery, Khyber College of Dentistry, Peshawar. *JKCD*, 2012.2(2):50-53
26. Kim JC, Choi SS, Wang SJ, Kim SG. Minor complications after mandibular third molar surgery: type, incidence and possible prevention. *Oral Surg Oral Med Oral Pathol Oral Radiol Endod.* 2006;102:4-11.
27. Eliasson S, Heimdahl A, Nordenram A. Pathological changes related to long-term impaction of third molars. A radiographic study. *Int J Oral Maxillofac Surg.* 1989;18(4):210–212.
28. Morris CR, Jerman AC. Panoramic radiographic survey: a study of embedded third molars. *J Oral Surg* 1971;29:122-125
29. Kramer RM, Williams AC. The incidence of impacted teeth. *Oral Surg Oral Med Oral Pathol.* 1970;29(2):237–241.
30. Ramamurthy A, Pradha J, Jeeva S, Jeddy N, Sunitha J, Kumar S. Prevalence of mandibular third molar impaction and agenesis: a radiographic south Indian study. *J Indian Acad Oral Med Radiol* 2012;24(3):173-176
31. Olasoji HO, Odunsaya SA. Comparative study of third molar impaction in rural and urban areas of South-western Nigeria. *Odonto-Stomatologie Tropicale.* 2000; 90:25-29.
32. Byahatti S, Ingafou MSH. Prevalence of eruption status of third molars in Libyan students. *Dental Research Journal*, 2012.9;2:152-157
33. Jaffar RO, Mon Mon TO. Impacted mandibular third molars among patients attending Hospital Universiti Sains Malaysia. *Archives of Orofacial Sciences* (2009),4(1):7-12
34. Almendros-Marqués N, Berini-Aytés L, Gay-Escoda C. Influence of lower third molar position on the incidence of preoperative complications. *Oral Surg Oral Med Oral Pathol Oral Radiol Endod.* 2006;102:725-32.
35. Monaco G, Montevicchi M, Bonetti GA, Gatto MR, Checchi L. Reliability of panoramic radiography in evaluating the topographic relationship between the mandibular canal and impacted third molars. *J Am Dent Assoc.* 2004;135:312-8.
36. Blondeau F, Daniel NG. Extraction of Impacted Mandibular Third Molars: Postoperative Complications and Their Risk Factors. *JCDA;* 2007;73(4):325