



Use of colposcopy for detection of squamous intraepithelial lesions

Feda Omeragić^{1,2*}, Azur Tulumović^{1,3}, Ermina Iljazović^{1,4}, Amela Adžajlić⁵, Alija Šuko⁶, Larisa Mešić Đogic⁷, Vladimir Perendija⁸

¹Department of Gynecology and Obstetrics, University of Tuzla Medical Faculty, Tuzla, Bosnia and Herzegovina, ²Obstetrics and Gynecology Practice "Omeragić", Tuzla, Bosnia and Herzegovina, ³Obstetrics and Gynecology Clinic, University Clinical Centre Tuzla, Tuzla, Bosnia and Herzegovina, ⁴Institute for Pathology, University Clinical Centre Tuzla, Tuzla, Bosnia and Herzegovina, ⁵Obstetrics and Gynecology Department, Health Centre Tuzla, Tuzla, Bosnia and Herzegovina, ⁶Obstetrics and Gynecology Department, Cantonal Hospital "Dr Safet Mujić", Mostar, Bosnia and Herzegovina, ⁷Obstetrics and Gynecology Department, General Hospital, Tešanj, Bosnia and Herzegovina, ⁸Obstetrics and Gynecology Department, Clinical Centre, Banjaluka, Bosnia and Herzegovina

ABSTRACT

Introduction: Pap smear, the main tool of cervical cancer screening is not always available, but some patients are in urgent need for proper diagnostic. Aim of this article was to investigate accuracy of colposcopy for detection of squamous intraepithelial lesions of low or high grade (LGSIL, HGSIL) and to promote colposcopy as useful tool for detection of patients in need for immediate further diagnostics.

Methods: Prospective multicentric study performed in B&H in 2012-2014 included 87 patients with colposcopic images related to squamous intraepithelial lesion (SIL) who formed experimental group: 56 patients with colposcopic images related to LGSIL and 31 patients related to HGSIL. Control group included 50 patients without colposcopic abnormalities. To test accuracy of colposcopy, PAP smear and histology were used. For statistical analysis χ^2 was used.

Results: 94.5% patients in experimental group had abnormal PAP test: 64.3% correlated to LGSIL ($\chi^2 = 60.48$ $P < 0.0001$), while 64.5% correlated to HGSIL ($\chi^2 = 54.23$ $P < 0.0001$) Odds Ratio = 490; 95% CI = 42.024 to 5713.304). HGSIL was confirmed in 27 (87%) cases by histology (CIN II/CIN III). There were no statistically significant differences between colposcopic finding and histology results (Yates-corrected $\chi^2 = 0.33$ $P = .5637$).

Conclusions: This study showed high level of correlation between colposcopy and PAP results (63-64%) and to histology for HGSIL (87%). In absence of PAP test colposcopy could be used to select patients in need for biopsy.

Keywords: Papanicolaou test; cervical intraepithelial neoplasia; colposcopic surgical procedures

INTRODUCTION

Squamous intraepithelial lesion (SIL) starts at the cellular level as transformation and abnormal growth of squamous cells on the surface of the cervix. In the cervical channel intraepithelial lesion

*Corresponding author: Feda Omeragić,
M. Tita 157, 75000 Tuzla, Bosnia and Herzegovina
Phone: +387 35 262 622
E-mail: fedja_o@hotmail.com

Submitted March 27 2014 / Accepted June 1 2014



starts as squamous metaplasia, which includes proliferation of undifferentiated reserve cells, columnar cells and their transformation into the squamous cells. SIL begin as cellular change at low grade level (LGSIL) and during the time could advance to high grade lesion (HGSIL) and cervical cancer. When detected, SIL can be successfully treated at any stage. It is well known and scientifically proven fact that cervical cancer screening program decreases incidence of cervical cancer by detecting early stages of intraepithelial changes (SIL) using PAP test as main tool (1). For the patients with abnormal PAP smear, colposcopy is usually the next step. However, what happens if the cervical cancer screening is not available and there is lack of information about disease prevention possibility? What happens if PAP control depends only on patients' awareness of disease? In such circumstances usually, incidence of inoperable cervical cancer is very high. Where does Bosnia and Herzegovina stand in this respect?

Health system in Bosnia and Herzegovina does not provide cervical cancer screening at the any level (State level, Entity level, Cantonal level). System for education of patients does not exist. Even more, there is no cancer database. First official reports about cancer incidence including cervical cancer were published by Public Health Institute of Federation Bosnia and Herzegovina (PBIFB&H) in 2007. According to that Report cervical cancer is second most common cancer in females in the Federation Bosnia and Herzegovina (FB&H). Furthermore in the period 1996 -2007 there were 20-25/100.000 newly detected cervical cancers in Tuzla Canton. Only 20.3% of those cases were in operable stages (2).

If we do not have cervical cancer screening program and if we cannot provide a PAP test as frequently as needed (due to lack of means), could we use colposcopy to select patients who are in need for a kind of "immediate" PAP smear or even biopsy?

The aim of this article was to investigate accuracy of colposcopy for detection of squamous intraepithelial lesions (SIL) and to promote colposcopy as tool for detection of patients in need for immediate PAP smear in the health systems without screening program.

METHODS

Study design

This was prospective multi-centric study that took a place in Obstetrics and Gynecology practice Omeragić, Tuzla, Health Centre of Tuzla, Health Centre Teašanj, Cantonal Hospitals of Mostar and Clinical Centre Banjaluka, during the period January 2012 to January 2014.

Patients

The patients in the study were selected in accordance to colposcopic criteria for squamous intraepithelial lesions.

Experimental group marked as Group A was formed by 87 patients. They were selected by means of colposcopy which showed one or more colposcopic images (markers) related to squamous intraepithelial lesion (SIL).

Colposcopic assessment of lesions was based on the following characteristics: location of the lesion related to Transformation zone (within or outside of the Transformation zone), reaction to 3-5% solution of acetic acid, color intensity, surface and borders, vascularization (inter-capillary distance), speed of emergence and time of duration.

Group A was divided in two subgroups: A1 and A2. Subgroup A1 included 56 patients with colposcopic images that are clearly defined as characteristics of LGSIL. Subgroup A2 included 31 patients with colposcopy images that are clearly defined as characteristics of HGSIL. Extensive lesion that was spread over the broad area of surface of the cervix, in the same time, was indication for biopsy.

A group of 50 patients without any colposcopic changes related to SIL formed Control group marked as Group B.

To test accuracy of colposcopy

1. PAP smear that was taken from all patients including experimental and control group was analyzed. Results were interpreted using Bethesda system: BCC - Benign Cellular Changes, ASCUS-atypical squamous cells undetermined significance, ASC H- atypical squamous cell which does not exclude HGSIL, LGSIL-low grade squamous cell intraepithelial

lesion, HGSIL-high grade squamous cell intraepithelial lesion (3).

2. Colposcopy directed biopsy was done in all patients from Subgroup A2. Histological results were analyzed as well.

Previous colposcopy and/or PAP smear were without any abnormality and were not taken 24 months prior to the beginning of the study. Cancers of any stage were not included in the study. Patients with unclear finding were not included in study.

Statistical analysis

Results were analyzed by descriptive and analytical statistics. Chi square test with or without Yates correction, Odds ratio, Fischer exact test were used. The level of significance was defined as $p < 0.05$. For statistical analysis software GrahPad Prism 6 for Windows, version 6 was used.

RESULTS

Experimental group and control group were homogenous. There were:

1. similar participation of nulliparous Group A 31 or 35%, Group B 16 or 32%,
2. similar distribution within the age groups 20-50 year
3. similar participation of those who previously did not have PAP smear and colposcopy Group A 31 or 35% and Group B 19 or 38%.

In experimental group (Group A) there were 87 patients with single or multiply markers for SIL. Out of all 82 (94.2%) had abnormal PAP test results including all varieties of Bethesda nomenclature.

In control group (Group B) out of all, 17 (34%) patients had abnormal PAP test. Difference is statistically significant ($\chi^2 = 18.91$ $P < 0.0001$: Odds Ratio = 3.027; 95% CI = 1.851 to 4.951) According to statistical analysis it means that patient with positive colposcopic markers for SIL have 3 times higher chances to have abnormal PAP test (Figure 1).

Out of all patients in experimental group there were 56 patients with colposcopic images defined as markers for LGSIL. They formed Subgroup A1. Those patients had markers located within the transformation zone (100%). Aceto-white (AW) epithelium was the most frequently seen (53 or 94.6%)

as a single marker (50 or 89.3%) or associated with vascular changes, mosaic (M) or/and punctuation (P) (3 or 5.35%).

When detected outside of Transformation zone (31 patients) more than one markers were seen most often. Aceto-white epithelium (AW) is most frequently seen, but only in two cases as a single marker (6.4%). Vascular changes (Mosaic, Punctuations) associated with AW epithelium were present in 29 (93.5%) cases. These images (markers) are defined as colposcopic criteria for HGSIL. Patients with such images formed Subgroup A2 (Table 1).

PAP smear was performed in all patients including control group. Distribution of PAP diagnosis (Bethesda categories) per groups was shown in Table 2.

Correlation between colposcopy and PAP diagnosis is shown of Figure 2.

In control group there were 17 (34%) PAP results marked as abnormal. In 12 (24%) cases it was ASC-US, atypical cells were related to inflammation or lack of hormonal activity, while only 8% had SIL.

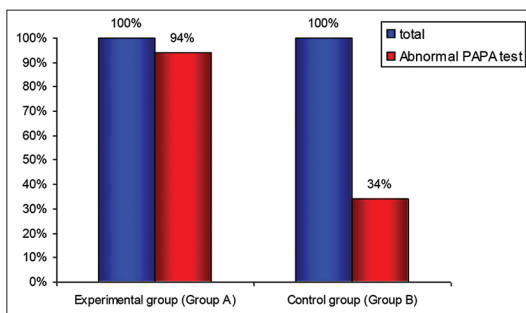


FIGURE 1. PAP test results in experimental and control group.

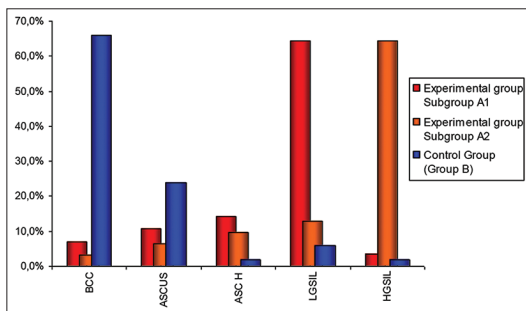


FIGURE 2. Results of PAP test compared to colposcopy results.

ASCUS was also seen in subgroups A1 (7.1%) and A2 (3.2%).

Analysis of LGSIL and HGSIL results showed significant differences compared to control group LGSIL ($\chi^2 = 60.48$ $P < 0.0001$); Odds Ratio = 141; 95% CI = 29.670 to 670.067), HGSIL ($\chi^2 = 54.23$ $P < 0.0001$ Odds Ratio = 490; 95% CI = 42.024 to 5713.304) which means that chances for LGSIL or HGSIL in PAP test are very high if colposcopy result are positive too.

All thirty-one (31) patients with extensive cervical tissue deterioration diagnosed by colposcopy as HGSIL (Subgroup A2) had biopsy. The following correlation between colposcopy and histopathology diagnosis was noticed (Table 3).

There are no statistically significant differences between colposcopic finding and histology results (Yates-corrected $\chi^2 = 0.33$ $P = .5637$) but there is a four times higher possibility that histology will show cervical intraepithelial lesion of medium grade (CIN II) and two times higher possibility that histology will show high grade dysplasia (CIN III) [Odds Ratio = 2.086; 95% CI (logit method)=

0.627202 to 6.940587] if colposcopic images related to HGSIL are present [Odds Ratio = 4; 95% CI (logit method) = 0.362 to 44.112].

DISCUSSION

Correlation between colposcopy and PAP, including all varieties of Bethesda nomenclature is high. Out of all 94.2% patient had both colposcopy and PAP results abnormal. According to statistical analyses patient with present colposcopic images (markers) for SIL have 3 times higher chances to have abnormal PAP test. Such results show that colposcopy markers have high accuracy in detection of cellular pathology. High level of correlation is reported by other researches (3-6). PAP test results correlate with colposcopic staging, too: 64.3% for LGSIL ($\chi^2 = 60.48$ $P < 0.0001$), 64.5% for HGSIL ($\chi^2 = 54.23$ $P < 0.0001$). In literature similar results are shown. Parvin at all reported correlation in 76.1% patients. Koigi-Kamau R at all reported correlation in 59-65% cases (7-9).

Biopsy or Loop excision of transformation zone (LETZ) was performed in 31 patients from subgroup A2/HGSIL. Medium and high grade intraepithelial dysplasia (CIN II/CIN III) were found by histology in 87% cases. There are no statistically significant differences between colposcopic finding and histology results (Yates-corrected $\chi^2 = 0.33$ $P = .5637$). Correlation between colposcopic findings and histology studied by many researchers showed high level of correlation. Savage EW at all reported accuracy of directed biopsies in 96% cases (10). Boelter WC 3rd at all found 96 - 98% correlation between the colposcopic findings, biopsies and cone specimens (11). Recent study by Boicea A at all showed correlation of 78.5% in the CIN I category, 84% in the CIN II category, 88.6% in the CIN III category (12).

ASC-H was detected in 12% patients in Group A. However, ASC-H does not exclude LG or HG SIL (13-17). In the same time 34% abnormal PAP smear results in control group additionally confirm hypothesis that the tissue architecture is not necessarily deteriorated from the beginning, particularly in cases of HPV infection.

Those patients were selected for intense follow-up. Same protocol were reported by other researchers (14,18,19).

TABLE 1. Frequency of the basic colposcopic images (markers)

	AW Epithelium N (%)	Mosaic N (%)	Punctation N (%)	Total
*Subgroup A1	53 (94.6)	1 (1.78)	1 (1.78)	56
**Subgroup A2	31 (100)	28 (90.3)	29 (83.5)	31

*Colposcopic images related to LGSIL; **Colposcopic images related to HGSIL

TABLE 2. PAP test results

Groups	BCC N (%)	ASC-US N (%)	ASC-H N (%)	LGSIL N (%)	HGSIL N (%)
*Subgroup A1	4 (7.1)	6 (10.7)	8 (14.3)	36 (64.3)	2 (3.5)
**Subgroup A2	1 (3.2)	2 (6.4)	3 (9.6)	4 (12.9)	20 (64.5)
†Group B	33 (66)	12 (24)	1 (2)	3 (6)	1 (2)

*Colposcopic images related to LGSIL; **Colposcopic images related to HGSIL; †No colposcopic abnormalities

TABLE 3. Results of histology - Subgroup A2*

Lesion	CIN I N (%)	CIN II N (%)	CIN III N (%)
Patients	2 (6.4)	18 (58)	11 (35.4)

*Subgroup A2, Colposcopic images related to HGSIL

CONCLUSIONS

Colposcopy is useful method for detection of early stages of SIL. This study showed high level of correlation between colposcopy and both, PAP test and histology. In the absence of cancer screening program and regular frequency of PAP smear diagnostics or if PAP test is not available, it can be used as a non-invasive, inexpensive and accurate tool.

CONFLICT OF INTEREST

The authors declare no conflict of interest. No specific funding was received for this study.

REFERENCES

1. Massad LS, Einstein MH, Huh WK et al. 2012th Updated Consensus Guidelines for the Management of Abnormal Cervical Cancer Screening Tests and Cancer Precursors. *J Low Genit Tract Dis* 2013;17(5):S1-S27 <http://dx.doi.org/10.1097/LGT.0b013e318287d329>.
2. Iljazović E, Kesić V. Patologija cervikalne epitelne neoplazije. Univerzitet u Tuzli. Grin, Gračanica; 2011.
3. Solomon D, Davey D, Kurman R, et al. The 2001 Bethesda System: terminology for reporting results of cervical cytology. *JAMA*. 2002;28(16):2114–9 <http://dx.doi.org/10.1001/jama.287.16.2114>.
4. Singer A, Monaghan J. M, QuekS.C., Deery A.R.S. Lower Genital Tract Precancer. Turin Italy: Blackwell Science Ltd; 2000 <http://dx.doi.org/10.1002/9780470760093>.
5. González SJL, Pérez GC, Celorio AG, Chávez BJ, Ríos MFA. Cytologic correlation between the Bethesda system and colposcopy biopsy. *Ginecol Obstet Mex*. 1998;66:330-4.
6. Cervical cancer in adolescents: screening, evaluation, and management. Committee Opinion No. 463. American College of Obstetricians and Gynecologists. *Obstet Gynecol*. 2010;116:469–72 <http://dx.doi.org/10.1097/AOG.0b013e3181eeb30f>.
7. Parvin S, Kabir N, Lipe YS, Nasreen K, Nurul- Alam KM. Correlation of pap smear and colposcopic finding of cervix with histopathological report in a group of patient attending in a tertiary hospital. *J Dhaka Medical College*. 2013;22(1):39-44 <http://dx.doi.org/10.3329/jdmc.v22i1.15604>.
8. Koigi-Kamau R, Kabare LW, Machoki JM. Impact of colposcopy on management outcomes of patients with abnormal cervical cytology. *East Afr Med J*. 2007;84(3):110-6.
9. Gadre SS, Gupta SG, Gadre AS. Descriptive analytical study looking for agreement between colposcopic cervical findings and cervical exfoliative cytology. *Int J Reprod Contracept Obstet Gynecol*. 2013;2(3):402-405 <http://dx.doi.org/10.5455/2320-1770.ijrcog20130928>.
10. Savage EW. Correlation of colposcopically directed biopsy and conization with histologic diagnosis of cervical lesions. *J Reprod Med*. 1975;15(6):211-3.
11. Boelter WC 3rd, Newman RL. The correlation between colposcopic grading, directed punch biopsy and conisation. *Am J Obstet Gynecol*. 1975;122(8):945.
12. Boicea A, Pătrașcu A, Șurliu V, Iliescu D, Schenker M, Chiuțu L. Correlations between colposcopy and histologic results from colposcopically directed biopsy in cervical precancerous lesions Rom J Morphol Embryol. 2012;53(3):735–741.
13. Sherman ME, Castle PE, Solomon D. Cervical cytology of atypical squamous cells-cannot exclude high-grade squamous intraepithelial lesion (ASC-H): characteristics and histologic outcomes. *Cancer* 2006;108:298–305 <http://dx.doi.org/10.1002/cncr.21844>.
14. Apgar BS, Kittendorf AL, Bettcher CM, Wong J, Kaufman AJ. Update on SCCP consensus guidelines for abnormal cervical screening tests and cervical histology. *Am Fam Physician* 2009;80:147-155.
15. American Society for Colposcopy and Cervical Pathology. Management of women with atypical squamous cells of undetermined significance (ASC-US). Hagerstown (MD): ASCCP; 2007.
16. Kim JJ, Wright TC, Goldie SJ. Cost-effectiveness of alternative triage strategies for atypical squamous cells of undetermined significance. *JAMA* 2002;287:2382 <http://dx.doi.org/10.1001/jama.287.18.2382>.
17. Darragh TM, Colgan TJ, Thomas Cox J, et al. The Lower Anogenital Squamous Terminology Standardization project for HPV-associated lesions: background and consensus recommendations from the College of American Pathologists and the American Society for Colposcopy and Cervical Pathology. *Int J Gynecol Pathol* 2013;32:76 <http://dx.doi.org/10.1097/PGP.0b013e31826916c7>.
18. Waxman AG, Chelmos D, Darragh TM, et al. Revised terminology for cervical histopathology and its implications for management of high-grade squamous intraepithelial lesions of the cervix. *Obstet Gynecol*. 2012;120:1465.
19. Ferlay J, Shin HR, Bray F, Forman D, Mathers C and Parkin DM. GLOBOCAN 2008, Cancer Incidence and Mortality Worldwide: IARC CancerBase No.10 Lyon, France: International Agency for Research on Cancer; 2010.[cited 2013 October 28]. Available from: <http://globocan.iarc.fr>.