



Modern treatment of patent ductus arteriosus – Single center experience

Senka Dinarević, Almira Kadić*, Zijo Begić, Mirza Halimić, Emina Vukas

Pediatric clinic, University clinical centre Sarajevo, Patriotske lige 81, Sarajevo, Bosnia and Herzegovina

ABSTRACT

Introduction: Transcatheter closure is a treatment choice for the most children with patent ductus arteriosus (PDA). The closure of the ductus is indicated in any child or adolescent with developed symptoms of significant L-R shunt. The aim of this article is to present our results in 5 years treatment of patients with PDA and their outcome.

Methods: From 2009 to 2014, 30 patients underwent a transcatheter closure of PDA at Centre for Heart and Pediatric clinic of Clinical University Centre of Sarajevo. Aortic angiogram was performed to evaluate the size, position, and shape of the duct for selection of appropriate occluder device type and size. All procedures were performed by local team of cardiologists from the Department of Cardiology, Pediatric clinic, with invasive cardiologists team from Sweden and Austria. Echocardiography was repeated at intervals of 24 hours, then 1 month, 3 months, and 1 year after the procedure to assess the outcome.

Results: Thirty patients underwent transcatheter closure of PDA during the study period. PDA of ≤ 2.0 mm was present in 8 patients and they underwent PDA closure with coils, while 22 patients had PDA diameter ≥ 2 mm, and they were treated by Amplatzer duct occluder (ADO). Only in 2 (6.2%) patients complications have been observed. The length of hospital stay after the treatment was two to three days.

Conclusion: Transcatheter closure of PDA is a modern, safe and efficient method that ensures a faster recovery of the patients, shortens the length of hospitalization.

Keywords: PDA; Transcatheter closure; occluder device; coil; ADO

INTRODUCTION

Patent Ductus Arteriosus (PDA) is a common form of congenital heart disease. Knowledge of the pathophysiology, clinical implications and management of patent ductus arteriosus (PDA) is a very

important task for pediatricians-cardiologists and adult cardiologists. In the last three decades transcatheter closure of PDA has largely replaced surgical ligation (1).

PDA represents vascular structure that connects the proximal part of the descending aorta to the main pulmonary artery (MPA), localized to the left branch of the pulmonary artery (LPA). PDA appears in certain syndromes such as: Down syndrome, Wolf-Hirschhorn syndrome, Carpenter syndrome, Holt-Oram syndrome (2).

*Corresponding Author: Almira Kadić, Pediatric Clinic, University clinical centre Sarajevo, Patriotske lige 81, 71000 Sarajevo, Bosnia and Herzegovina, Tel: +39761260052, E-mail: almira.kadic@yahoo.com

Submitted September 25 2014 / Accepted December 20 2014



The incidence of PDA in term newborns is 1/2000 births, representing 5% to 10% of all congenital heart anomalies, and sex distribution is 2:1 in favor of females (3). Hemodynamic repercussions depend on ductal resistance, which are affected by the size and appearance of the duct, the pressure gradient (PG) between the aorta and pulmonary artery. Most patients are asymptomatic. If there is a larger left-right shunt (L-R shunt), there is intolerance to effort. A significant PDA that is not closed, may lead to sequelae such as congestive heart failure, pulmonary hypertension, pulmonary vascular obstructive disease, recurrent chest infection, ductal aneurism and an increased risk of infective endocarditis. (4-6). Echocardiography is a noninvasive diagnostic method that provides the information about hemodynamics of PDA. Transcatheter closure is the method of choice for the most children with patent ductus. The closure of the ductus is indicated in any child or adolescent with developed symptoms of significant L-R shunt. Asymptomatic patients with significant L-R shunt, through PDA and enlargement of the left heart cavities, are definitely in a group of patients for PDA closure, in order to prevent the development of complications (7).

In patients with a small shunt - "silent" ductus, the closing should be consider due to later complications. However, considering that this is a safe, effective method with minimal morbidity, it is recommended to close the PDA at any age (8,9).

Contraindications for transcatheter closure of PDA are: age of the child is less than 6 months; the presence of blood clots in the heart and blood vessels, or general disorder of coagulation system; body weight less than 6 kg; presence of infection; increased pressure in the pulmonary artery (PA) (10).

Common complications of transcatheter closure of PDA include: bleeding, arrhythmia, residual shunt, left pulmonary artery (LPA) obstruction, protrusion of the device into the aorta, embolization of the device (11,13).

In this study, we are reporting our experience during past five years with PDA closure using detachable coils and Amplatzer duct occluder (ADO) and outcome of the patients.

METHODS

Study design

All patients who had undergone transcatheter closure of PDA between 2009 and 2014 on Pediatric clinic and Center for Heart, University Clinical Center Sarajevo, were included in this retrospective study. 30 patients underwent transcatheter closure of PDA. All procedures were performed by local team of cardiologists from the Department of Cardiology, Pediatric clinic with a team from Sweden and Austria.

The exclusion criteria included those who have been found to be not suitable for device closure after reviewing. We excluded one patient with presence of Pulmonary arterial hypertension and one that was unsuccessful.

All patients had clinical evaluation and echocardiographic confirmation of the diagnosis. A complete diagnostic evaluation and assessment of hemodynamics (evaluation of pulmonary vascular resistance, type of shunt) before transcatheter closure is of a crucial importance.

This was followed by an aortic angiography to evaluate the anatomy (size, position and shape) of the ductus arteriosus for appropriate device choice for closure: type and size (Table 1). It is very important to determine the minimum and maximum diameter (aortic ampulla), the length and shape of the ductus before performing closing procedure.

Size is determined by minimal ductal diameter on angiographic view. Before starting the procedure the patient must be under general anesthesia along with monitoring of vital parameters. Devices used for occlusion were detachable coils and ADOs. Detachable coils (14) were used for patients with small PDAs of ≤ 2.5 mm at the narrowest diameter (Figure 1A). ADOs were used for PDAs that were > 2.5 mm (Figure 1B).

TABLE 1. Classification of PDA based on size

Type	Description
Silent PDA	Less than 1.5 mm and no murmur
Very small PDA	≤ 1.5 mm with audible murmur
Small PDA	1.5-3 mm and murmur
Moderate PDA	3-5 mm and murmur
Large PDA	> 5 mm and murmur




FIGURE 1. Gianturco coil (cylindrical shape) (A) and Amplatzer duct occluder (B)

Protocol of PDA closure implies that patients are undergoing right and left heart catheterization, using 4Fr or 5Fr sheath, placed in the femoral artery and 6Fr sheath in the femoral vein. Heparin is administered during the procedure. After selecting occluders ($\geq 1-2$ mm larger than the minimum size of a PDA), it was connected with the catheter system and submerged in sterile water to avoid the presence of air drawn into the delivery system.

The coil are delivered into the main pulmonary artery. The guide wire is fixed in position and the catheter is slowly withdrawn over the wire into the descending aorta, thus extruding the remaining coil into the aortic end of the ductal ampulla.

If the position is adequate, occluder is released. A second aortic angiogram was performed after device deployment. After the procedure, it is recommended the next two doses of antibiotics and aspirin therapy at a dose of 2-3 mg/kg/day, which is given the next 4-6 months. Patients than had follow-up in Pediatric Cardiology Clinic 24 hours after procedure (vital signs, x-ray and echocardiography). Further monitoring means repeated echocardiography after 1 month, 3 months and 1 year, when evaluation of: residual shunt, moving occluders, thrombus, aortic or pulmonary stenosis, is performed.

RESULTS

Thirty patients underwent transcatheter closure of PDA during the study period. Of these, 17 (57%) were girls and 13 (43%) were boys (Figure 2).

Age structure ranged of the treated patients from 1 year to 10 years. (Figure 3).

Eight patients had PDA of ≤ 2.0 mm at the narrowest diameter and they underwent PDA closure with coils and 22 patients with PDA diameter ≥ 2 mm, had their PDAs closed with ADOs (Figure 4).

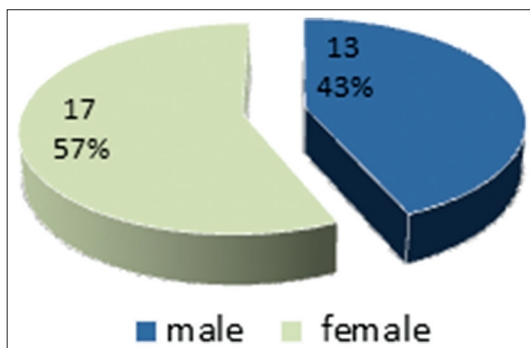


FIGURE 2. Sex structure of the treated patients

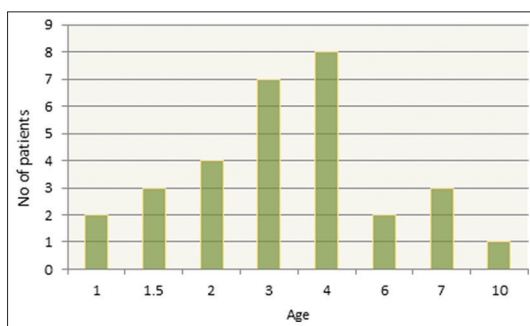


FIGURE 3. Age structure of the treated patients

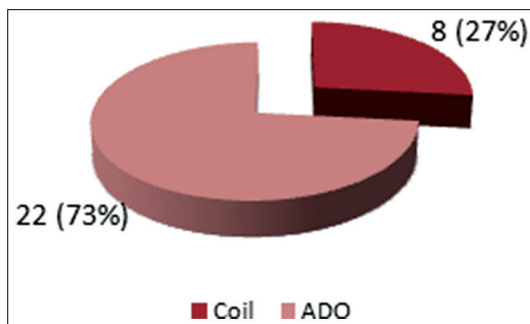


FIGURE 4. The type of occlude used

After the procedure, patients with closed PDA were treated at the Department of Cardiology, Pediatric Clinic, University Clinical Center in Sarajevo. The length of hospitalization after procedure is two days (28 patients) and three days in only 2 patients.

Only in 2 (6.2%) patients complications have been observed. In one patient, we detected transient myocardial ischemia. Device embolization occurred in one case, which is successfully retrieved back. There

were no significant residual PDA shunt during patients short postprocedure follow up period.

DISCUSSION

PDA closure is indicated for several reasons: preventing the development of bacterial endocarditis, hypertensive pulmonary disease, aneurysm formation, and congestive heart failure.

In the majority of the world's cardiac centers, transcatheter closure of PDA is considered to be a standard type of treatment (1). Even though there is no clear consensus, the advantages of transcatheter closure is preferred because of the high success rates, shorter hospital stay, less blood loss, low rates of morbidity, without opening the patient's chest. This mode of treatment is particularly suitable in cases of cardiac and respiratory diseases in which the risk of surgery is increased (15).

A retrospective cohort study of nine representative publications, included in the meta-analysis from around the world, correlate benefit of different ways of treatment of PDA through a series of morphological and hemodynamic parameter (16). There was no significant difference in primary success rate and post procedure complications. The residual shunt was more frequent in the group of catheterized patients, while remarkable reduction in length of hospitalization was in catheterized patients (16-18).

Liddy et al. (19) in their retrospective study demonstrated a small percentage of residual shunt following patients after transcatheter closure, 1, 3 and 6 months (6.8, 1.7 and 1.1%). Arodiwe et al. (10) compared the success the closure of the PDA, the development of complications, using different types of occluders. Correlation analysis demonstrated that success of intervention largely depends on several factors: the experience of cardiologists, duct size, age and body weight. Diameter and morphology of the ductus had affected the selection of occluder type and success. Development of complications was similar in both groups (coil and ADO).

Our study of 30 patients showed that the transcatheter closure of PDA has a great success, with a low complication rate. Follow up of all patients with implanted occluders requires a serious approach of well-trained cardiologist, who will on time recognize

any deviations in the positions and changing of hemodynamics.

CONCLUSION

In our five years experience in the treatment of PDA by transcatheter closure, this method demonstrated fast patient recovery, shorter length of hospitalization and no residual shunt on follow up.

CONFLICT OF INTERESTS

The authors declare no conflict of interest.

REFERENCES

1. Gray DT, Fyler DC, Walker AM, et al. Clinical outcomes and costs of transcatheter as compared with surgical closure of patent ductus arteriosus. *N Engl J Med.* 1993;329:1517-1523. <http://dx.doi.org/10.1056/NEJM199311183292101>.
2. Nora JJ. Multifactorial inheritance hypothesis for the etiology of congenital heart diseases: the genetic-environmental interaction. *Circulation.* 1968; 38: 604-617. <http://dx.doi.org/10.1161/01.CIR.38.3.604>.
3. Lloyd TR, Beekman RH III. Clinically silent patent ductus arteriosus. *Am Heart J.* 1994; 127: 1664-1665 <http://dx.doi.org/10.1016/0002-8703>.
4. Dyamenahalli U, Smallhorn JF, Geva T, Fournon JC, Cairns P, Jutras L, Hughes V, Rabinovich M, Mason CA, Hornberger LK. Isolated ductus arteriosus aneurysm in the fetus and infant: a multi-institutional experience. *J Am Coll Cardiol.* 2000; 36: 262-269. [http://dx.doi.org/10.1016/S0735-1097\(00\)00707-5](http://dx.doi.org/10.1016/S0735-1097(00)00707-5).
5. Cruickshank B, Marquis RM. Spontaneous aneurysm of the ductus arteriosus. *Am J Med.* 1958; 25: 140-149. <http://dx.doi.org/10.1016/0002-9343>.
6. Kerwin AJ, Jaffe FA. Post-operative aneurysm of the ductus arteriosus with fatal rupture of a mycotic aneurysm of a branch of the pulmonary artery. *Am J Cardiol.* 1959; 3: 397-403. <http://dx.doi.org/10.1016/0002-9149>.
7. Fisher RG, Moodie DS, Sterba R, Gill CC. Patent ductus arteriosus in adults—long term follow-up: nonsurgical vs surgical treatment. *J Am Coll Cardiol.* 1986; 8: 280-284. [http://dx.doi.org/10.1016/S0735-1097\(86\)80040-7](http://dx.doi.org/10.1016/S0735-1097(86)80040-7).
8. Verin VE, Saveliev VS, Kolody SM, Prokubovski VI. Results of transcatheter closure of the patent ductus arteriosus with the Botallooccluder. *J Am Coll Cardiol* 1993;22:1509 -14. [http://dx.doi.org/10.1016/0735-1097\(93\)90564-H](http://dx.doi.org/10.1016/0735-1097(93)90564-H).
9. Moore JW, George L, Kirkpatrick SE, et al. Percutaneous closure of the small patent ductus arteriosus using occluding spring coils. *J Am Coll Cardiol* 1994;23:759-65. [http://dx.doi.org/10.1016/0735-1097\(94\)90765-X](http://dx.doi.org/10.1016/0735-1097(94)90765-X).
10. O. Arodiwe, D. K. Adiele, J. M. Chinawa, V. Gouthami, K. S. Murthy, E. O. Obidike, et al.; Clinical Study of Trans-catheter Closure of Patent Ductus Arteriosus with Occluder Devices among Children Aged 9 Months to 18 Years *International Journal of TROPICAL DISEASE & Health*4(1): 31-44, 2014.
11. Cambier PA, Kirby WC, Wortham DC, et al. Percutaneous closure of the small (less than 2.5mm) patent ductus arteriosus using coil embolization. *Am J Cardiol.* 1992;69:815-816. [http://dx.doi.org/10.1016/0002-9149\(92\)90514-Y](http://dx.doi.org/10.1016/0002-9149(92)90514-Y).
12. Patent Ductus Arteriosus (PDA) Closure Device. <http://professional.sjm.com/products/sh/heart-occluders/pda-closure-devices> (Accessed on February 07, 2014).
13. Dutta S, Mihailovic A, Benson L, et al. Thoracoscopic ligation versus coil

- occlusion for patent ductus arteriosus: a matched cohort study of outcomes and cost; *Surg Endosc* 2008; 22:1643. <http://dx.doi.org/10.1007/s00464-007-9674-1>.
14. U.S. Food and Drug Administration Medical Devices. Devices/Products and Medical Procedures/Device Approvals and Clearances/default.htm (Accessed on January 20, 2014).
 15. Sheridan BJ, Ward CJ, Anderson BW, et al. Transcatheter closure of the patent ductus arteriosus: an intention-to-treat analysis. *Heart Lung Circ*. 2013;22:428–432. <http://dx.doi.org/10.1016/j.hlc.2012.12.007>.
 16. Hawkins JA, Minich LL, Tani LY, et al. Cost and efficacy of surgical ligation versus transcatheter coil occlusion of patent ductus arteriosus. *J Thorac Cardiovasc Surg*. 1996;112:1634–1639. <http://dx.doi.org/10.1016/S0022-5223>.
 17. Li T, Pan GT, Yang Y. The comparison between percutaneous transcatheter Amplatzer occluder and surgical closure in patent ductus arteriosus patients. *Clin Med*. 2003;23:23.
 18. Ruan J, Deng XH, Chen J, et al. Comparison between Amplatzer duct occluder and surgical closure on patent ductus arteriosus. *Guangxi Med J*. 2006;28:2.
 19. Liddy S, Oslizlok P, Walsh KP. Comparison of the results of transcatheter closure of patent ductus arteriosus with newer amplatzer devices. *Catheter Cardiovasc Interv*. 2013;82:253–259 <http://dx.doi.org/10.1002/ccd.24768>.