



# Classical surgical approach and treatment with clips of extracranial internal carotid artery berry aneurysm

Haris Vukas<sup>1\*</sup>, Nedžad Rustempašić<sup>1</sup>, Samra Kadić-Vukas<sup>2</sup>, Dragan Totić<sup>1</sup>, Muhamed Djedović<sup>1</sup>, Sid Solaković<sup>1</sup>

<sup>1</sup>Vascular Surgery, University Clinical Centre of Sarajevo, Sarajevo, Bosnia and Herzegovina, <sup>2</sup>Department of Neurology, Cantonal Hospital Zenica, Zenica, Bosnia and Herzegovina

## ABSTRACT

**Introduction:** We can define extracranial carotid artery aneurysm (ECAA) as bulb dilatation greater than 200% of the diameter of the internal carotid artery (ICA) or in a case of common carotid artery (CCA) greater than 150% of the diameter. Surgical intervention is required for the treatment of this disease.

**Case Report:** This study presents an open vascular surgical procedure to resolve ECAA. We report a case of 61 years old woman with an extracranial internal carotid artery berry aneurysm, presented with a headache and dizziness when turning the head aside. Classic open surgery was performed and the lumen of berry aneurysm was separated with three clips from the lumen of ICA.

**Conclusions:** The open surgical approach is the method of choice for the treatment of extracranial internal carotid artery pathological conditions.

**Keywords:** Berry aneurysm; carotid artery; open surgical procedure; clips

## INTRODUCTION

We can define an arterial aneurysm as increased diameter of an artery, at least 50% of the normal arterial diameter (1). Carotid bifurcation is 40% greater in diameter than the distal internal carotid artery (ICA). This threshold is not difficult to

achieve. The definition of extracranial carotid artery aneurysm (ECAA) is bulb dilatation with a diameter greater than 200% of the ICA diameter or 150% of the common carotid artery (CCA) diameter (2). This definition is used in many reports and studies of ECAA and is helpful to delineate physiologic dilatation of the carotid bulb. Most of the ECAA aneurysms are located at the bifurcation of the common carotid artery or at the proximal ICA, where atherosclerosis is expressed the most, and they tend to be fusiform. Atherosclerotic aneurysms that do not involve the carotid bifurcation are frequently berry and occur in patients with severe arterial

\*Corresponding author: Haris Vukas, Vascular Surgery, University Clinical Centre of Sarajevo, Čekaluša 88, 71000 Sarajevo, Bosnia and Herzegovina, Phone: +38761216182, E-mail: haris.vks77@gmail.com

Submitted: 25 January 2016/Accepted: 6 May 2016

DOI: <http://dx.doi.org/10.17532/jhsci.2016.317s>



hypertension. Most bilateral, atraumatic ECAs are of the berry type.

Although common surgical procedures performed on carotid arteries include stenotic lesions, vascular interventions on the aneurysms of carotid arteries are less frequent, include about 2% of all carotid artery interventions (2,3). The etiology of carotid artery aneurysms is not entirely known because only several vascular centers have accumulated sufficient data and experience to try to explain the genesis (3).

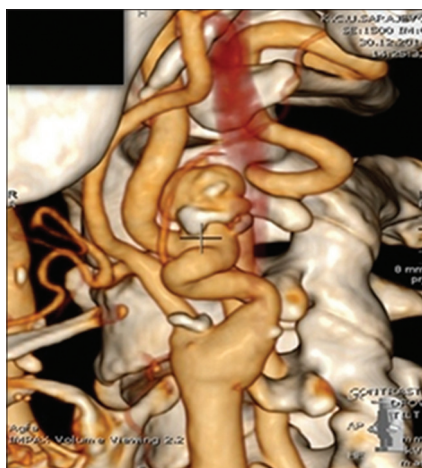In a study conducted at the Texas Heart Institute, the most common symptoms regarding ICA aneurysms (43% of patients) were related to cerebrovascular ischemia (3). Considering the high risk of cerebrovascular incidents, in the case of carotid aneurysms, we can explain why many vascular surgeons prefer intervention for most of these aneurysms.

We report a case of 61-year-old woman with an extracranial berry aneurysm of the internal carotid artery.

## CASE REPORT

A 61 year old woman was admitted to the Clinic of Vascular Surgery of the University Clinical Centre in Sarajevo with symptoms: a headache and vertigo during rotation of the head. According to the color Doppler finding obtained from the patient, kinking and berry aneurysm of the left internal carotid artery were suspected. She was a smoker and had a history of hypertension, type 2 diabetes mellitus, and hypothyroidism treated with levothyroxine. There was no prior history of neck injuries, infections, cerebrovascular accidents, and allergies. The physical examination did not reveal a palpable pulsatile tumoroid formation. A berry aneurysm of the left ICA was confirmed by computed tomography angiography (CTA) with 3-D reconstructions, which revealed double kinking of the left ICA at 15 mm from the origin, partially thrombosed, and the berry aneurysm measuring 14.2x12.5mm in diameter, neck widths up to 4 mm. The distal portion of the left ICA preserved a width of circulating lumen (Figure 1).

Classic open surgical approach to the carotid artery with preservation of the neural structures (cranial nerves X and XII) was performed under regional anesthesia (cervical block using a 2% Xylocaine).



**FIGURE 1.** Computed tomography angiography (CTA) of the left internal carotid artery (ICA). A berry aneurysm of the left ICA was confirmed by CTA with 3-D reconstructions, which revealed double kinking of the left ICA at 15 mm from the origin, partially thrombosed, and the berry aneurysm measuring 14.2x12.5 mm in diameter, neck widths up to 4 mm. The distal portion of the left ICA preserved a width of circulating lumen.

After establishing vascular control by surgical dissection and preparation for clamping of the common, external, and internal carotid arteries, we approached and liberate the neck of berry aneurysm of 6 mm width from the neighboring structures. At that moment, there was a sudden deterioration of the patient general status. The patient began to complain of shortness of breath, chest pain, and numbness in the left hand. On the monitor there was ST depression and oxygen saturation decreased below 90%. The anesthesiologist urged speedy completion of the surgery and opened the possibility of thrombolytic treatment. The lumen of the berry aneurysm was separated from the ICA using three clips ETHICON LT 400.

Post-procedurally, the patient was confirmed termination of the problems that had appeared during the operation. The postoperative recovery laboratory findings (troponin, CK-MB and D-dimer) were in the range of reference values, the electrocardiogram (ECG) was normal, and there were no pathological findings or incidents in the cardiovascular and central nervous systems. The most significant postoperative complication, verified with laryngoscopy, was vocal paresis left for 5 days. On control laryngoscopy, hematoma in regression was found and

both vocal cords were in phonation and respiratory moving.

Control color Doppler did not record the existence of a berry aneurysm (Figure 2), with the presentation of kinking that leaves no repercussions on the flow (PSV 93.16 cm/32.83 cm you EDV/s) in ICA.

During regular controls, the patient did not have the same symptoms as before the surgical intervention. Mostly, she had the symptom of mild dizziness after sudden movement of the head. Control CTA was performed 6 months after the surgery (Figure 3). The left CCA had an adequate flow and preserved the width of the circulating lumen to 8 mm. In the area of bifurcation and the initial part of the ICA lamellar calcification was formed. After the surgical intervention, visualizing the area with metal clips no aneurysm was observed in the control physical examination. The distal ICA demonstrated preserved width of the circulating lumen and appropriate contours without visible defects in the contrast filling.

## DISCUSSION

Aneurysms of the extracranial parts of the carotid arteries have incidence from 0.8 to 1% and make 5% of all peripheral aneurysms (4-6). In elderly patients the cause of the disease is usually atherosclerosis. The etiology in younger patients includes: infections, trauma, vasculitis (with dissection), and fibromuscular dysplasia. The symptoms are in direct correlation with the etiology, location, and size of an aneurysm. There are three categories of the symptoms:

1. Compression which can cause hoarseness and dysphagia (6-10).

2. Rupture occurs predominantly in mycotic aneurysms (11,12).
3. The most serious complication of carotid artery aneurysms is an increased risk of thromboembolic incidents that cause a stroke.

Diagnosis of ECAA can be achieved by combining clinical and radiological findings which include: radiological confirmation by color Doppler, computerized tomography, and magnetic or digital subtraction angiography. A neurological deficit in patients after neck injuries is an alarm for the presence of a carotid artery aneurysm and should be excluded by radiological examinations. Because of a high rate of cerebral embolic complications and mortality, for patients with ECAA surgical treatment is strongly recommended.

Treatment of aneurysms located in the distal part of the ICA or near the base of the skull includes endovascular stenting (13-15), because classical surgical repair is not possible in this case (7,10,16). However, the endovascular manipulation is associated with the risk of stroke and an inability to apply the surgical approach in a case of complications (i.e., bleeding) (16,17).

According to a systemic review (18), endovascular stenting of the ICA aneurysms resulted in a stroke risk of 1.8%, cranial nerve injury of 0.5%, and a mortality risk of 4.1%. When patients with ECAA were exposed to the endovascular procedure, results were successful with a low complication rate.

A retrospective study conducted by Angiletta et al. on 26 aneurysms in 25 patients (19 men and 6 women), who underwent surgery between 1993 and 2010, showed the diversity of surgical techniques that were

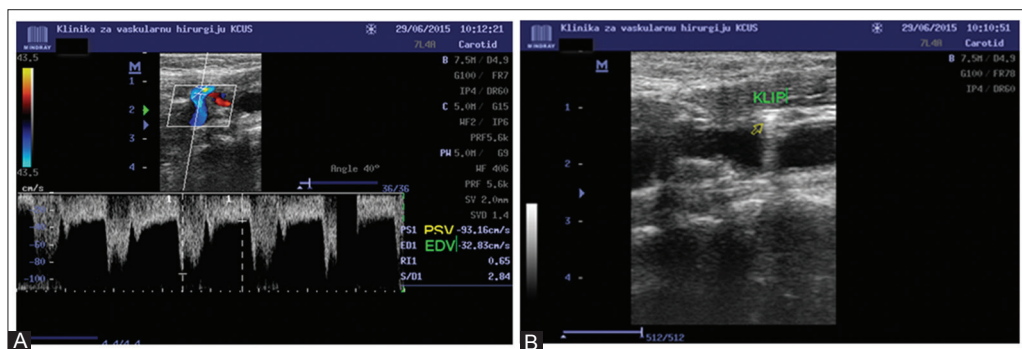
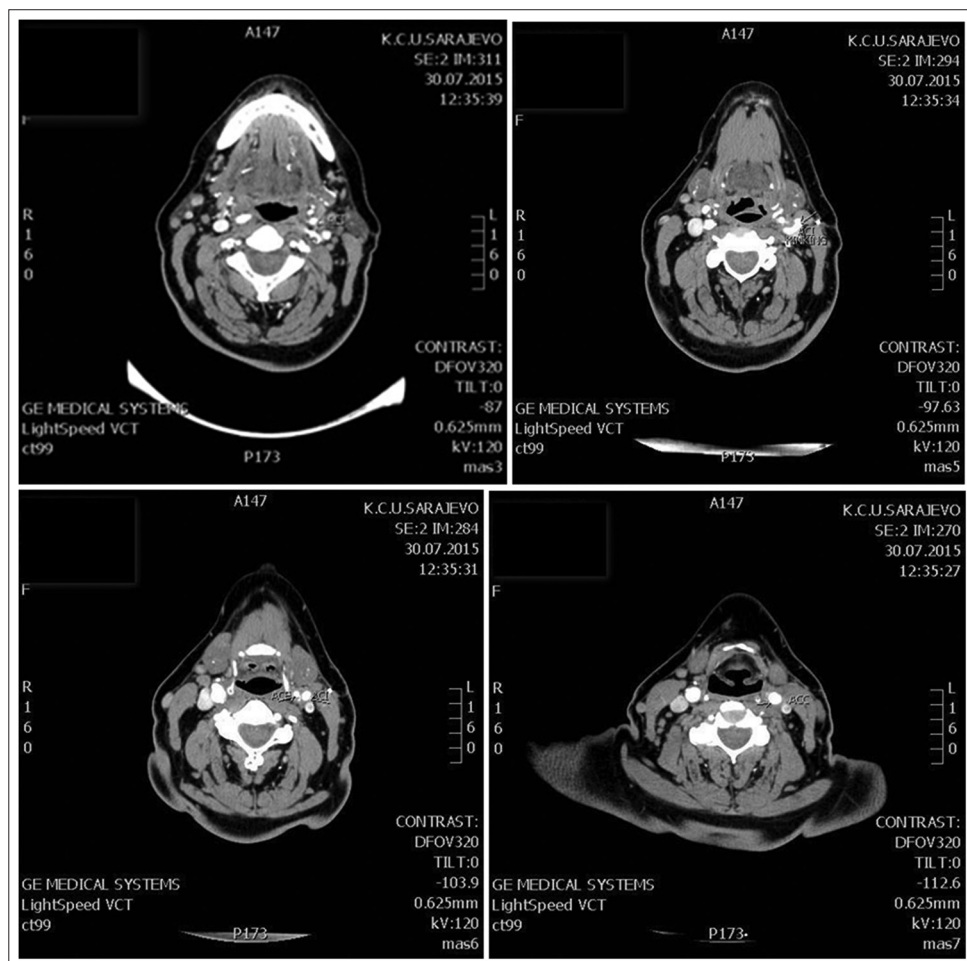


FIGURE 2. Control color Doppler (A) without repercussions on the flow, (B) no existence of a berry aneurysm.



**FIGURE 3.** Six months after the surgical repair, no aneurysm was observed with control computed tomography angiography. The distal internal carotid artery demonstrated preserved width of the circulating lumen and appropriate contours without visible defects in the contrast filling.

used: end-to-end carotid anastomosis, vein graft, polytetrafluoroethylene graft, aneurysmorrhaphy and a vein patch, and GORE VIABAHN endoprosthesis. Perioperative minor stroke occurred in 1 patient and transient cranial nerve injuries were observed in 2 patients. This study showed that surgical treatment is feasible and have an acceptable rate of stroke and cranial nerve injuries (19).

A retrospective review by Szopinski et al. showed that endovascular procedures allow treating extracranial aneurysms when open surgery is not recommended or not possible in special cases (20).

In the beginning, endovascular balloon occlusion, coil embolization, graft stenting, and similar

procedures demonstrated poor results because of different complications (the main complications were cerebral embolization and stent occlusion). Today, endovascular treatment offers more commotion for vascular surgeons in the treatment of ECAA with regard to surgical dexterity, especially in patients that were already exposed to open surgical interventions on carotid arteries (i.e., pseudoaneurysms as a complication).

## CONCLUSION

Due to the findings that lay on the experience of neurosurgeons, we can look at this case as a pioneer step in proving that one surgical technique can be applied

in various cases. After all, open surgical approach, with greater creativity for a vascular surgeon, is the method of choice for the treatment of extracranial internal carotid artery pathological findings.

## CONFLICT OF INTEREST

The authors declare no conflict of interest.

## REFERENCES

- Johnston KW, Rutherford RB, Tilson MD, Shah DM, Hollier L, Stanley JC. Suggested standards for reporting on arterial aneurysms. Subcommittee on Reporting Standards for Arterial Aneurysms, Ad Hoc Committee on Reporting Standards, Society for Vascular Surgery and North American Chapter, International Society for Cardiovascular Surgery. *J Vasc Surg.* 1991;13(3):452-8.  
<http://dx.doi.org/10.1067/mva.1991.26737>.
- de Jong KP, Zondervan PE, van Urk H. Extracranial carotid artery aneurysms. *European J Vasc Surg.* 1989;3(6):557-62.  
[http://dx.doi.org/10.1016/S0950-821X\(89\)80132-X](http://dx.doi.org/10.1016/S0950-821X(89)80132-X).
- Forbes TL, Nie RG, Kirk Lawlor D. Sacular Aneurysm of the Extracranial Internal Carotid Artery. *EJVES Extra.* 2003;5(4):49-51.  
[http://dx.doi.org/10.1016/S1533-3167\(03\)00049-9](http://dx.doi.org/10.1016/S1533-3167(03)00049-9).
- El-Sabrou R, Cooley DA. Extracranial carotid artery aneurysms: Texas Heart Institute experience. *J Vasc Surg.* 2000;31(4):702-12.  
<http://dx.doi.org/10.1067/mva.2000.104101>.
- Ilic N, Koncar I, Dragas M, Markovic M, Kostic D, Davidovic L. Aneurysm of the kinked extracranial internal carotid artery: extraordinary union. *Am Surg.* 2010;76(11):E214-5.
- Mishwani AH, Haleem A, Kiani KA. Giant aneurysm of the extracranial internal carotid artery. *J Coll Physicians Surg Pak.* 2010;20(5):345-6. DOI: 05.2010/JCPSP.345346.
- Lane RJ, Weisman RA, Savino PJ, Schatz NJ. Aneurysm of the internal carotid artery at the base of the skull: an unusual cause of cranial neuropathies. *Otolaryngol Head Neck Surg* (1979). 1980;88(3):230-2.  
<http://dx.doi.org/10.1177/019459988008800307>.
- Oruckaptan HH, Ozcan OE. Giant extracranial internal carotid artery aneurysm: a rare presentation with an oropharyngeal mass. *Otolaryngol Head Neck Surg.* 2001;125(5):571-3.  
[http://dx.doi.org/10.1016/s0194-5998\(01\)81112-8](http://dx.doi.org/10.1016/s0194-5998(01)81112-8).
- Vasileiadis I, Kapetanakis S, Fiska A, Vasileiadis D, Dimitriou T. A giant aneurysm of the internal carotid artery, which caused dysphagia: case study and short review of literature. *Folia Morphol* (Warsz). 2010;69(4):267-70.
- Wilding LJ, Howlett DC, Anderson HJ, Sangle PD, Violaris N, Evans GH. Extracranial internal carotid artery aneurysm presenting as symptomatic hypoglossal and glossopharyngeal nerve paralysis. *J Laryngol Otol.* 2004;118(2):150-2.  
<http://dx.doi.org/10.1258/002221504772784649>.
- Angle N, Dorafshar AH, Ahn SS. Mycotic aneurysm of the internal carotid artery: a case report. *Vasc Endovascular Surg.* 2003;37(3):213-7.  
<http://dx.doi.org/10.1177/153857440303700309>.
- O'Connell JB, Darcy S, Reil T. Extracranial internal carotid artery mycotic aneurysm: case report and review. *Vasc Endovascular Surg.* 2009;43(4):410-5.  
<http://dx.doi.org/10.1177/1538574409340590>.
- Hosoda K, Fujita S, Kawaguchi T, Shibata Y, Tamaki N. The use of an external-internal shunt in the treatment of extracranial internal carotid artery saccular aneurysms: technical case report. *Surg Neurol.* 1999;52(2):153-5.  
[http://dx.doi.org/10.1016/S0090-3019\(99\)00039-7](http://dx.doi.org/10.1016/S0090-3019(99)00039-7).
- Juszkat R, Wróbel M, Golusiński W, Szyfter W, Chęciński P, Oszkiniś G. Stent-graft treatment of extracranial internal carotid artery aneurysm. *Eur Arch Otorhinolaryngol.* 2005;262(10):826-9.  
<http://dx.doi.org/10.1007/s00405-005-0914-5>.
- Trinidad-Hernández M, Introcaso JH, White JV. Combined open and endovascular treatment of a saccular aneurysm and redundant loop of the internal carotid artery. *J Vasc Surg.* 2006;44(3):642-6.  
<http://dx.doi.org/10.1016/j.jvs.2006.05.015>.
- Ktenidis K, Lioupis A, Megalopoulos A, Antoniadis K, Kiskinis D. New exposure technique for management of giant internal carotid artery aneurysm. *J Vasc Surg.* 2011;54(2):522-5.  
<http://dx.doi.org/10.1016/j.jvs.2010.12.060>.
- Biasi L, Azzarone M, De Troia A, Salcuni P, Tecchio T. Extracranial internal carotid artery aneurysms: case report of a saccular wide-necked aneurysm and review of the literature. *Acta Biomed.* 2008;79(3):217-22.
- Li Z, Chang G, Yao C, Guo L, Liu Y, Wang M, et al. Endovascular stenting of extracranial carotid artery aneurysm: a systematic review. *Eur J Vasc Endovasc Surg.* 2011;42(4):419-26. <http://dx.doi.org/10.1016/j.ejvs.2011.05.008>.
- Angiletta D, Pulli R, Marinazzo D, Frotino P, Maiellaro L, Regina G. Surgical and endovascular treatment of extracranial carotid artery aneurysms: early and long-term results of a single center. *Ann Vasc Surg.* 2014;28(3):659-64.  
<http://dx.doi.org/10.1016/j.avsg.2013.05.014>.
- Szopinski P, Ciostek P, Kielar M, Myrcha P, Pleban E, Noszczyk W. A Series of 15 patients with extracranial carotid artery aneurysms: surgical and endovascular treatment. *Eur J Vasc Endovasc Surg.* 2005;29(3):256-61.  
<http://dx.doi.org/10.1016/j.ejvs.2004.12.021>.