



# External auditory canal osteoma: A case report

Biserka Pigac<sup>1</sup>, Silvija Mašić<sup>2</sup>, Zdenka Hutinec<sup>3</sup>, Svjetlana Marić<sup>4\*</sup>, Valentina Mašić<sup>5</sup>

<sup>1</sup>Pathology, Cytology and Forensic Medicine Unit, Varaždin General Hospital, Varaždin, Croatia. <sup>2</sup>Clinic for Oncology and Nuclear Medicine, University Hospital Centre Sestre Milosrdnice, Zagreb, Croatia. <sup>3</sup>Department of Pathology, University Hospital Centre Zagreb, Zagreb, Croatia. <sup>4</sup>Department of Biology, Medical Faculty Osijek, University of Osijek, Osijek, Croatia. <sup>5</sup>Training and Education Center 'Vinko Bek', Zagreb, Croatia

## ABSTRACT

Osteoma is benign tumor composed of well- differentiated matured osseous tissue. Its presence in mandible and paranasal sinuses is common, yet appearance in external auditory canal is rare. We present a case of a 26- year- old male complaining of hearing loss and pain in the affected ear. Pathohistological analysis of surgically removed tissue revealed tumor consisted of mature trabecular bone, which represents benign lesion without tendency of metastasis.

**Keywords:** External auditory canal; histopathology; osteoma

## INTRODUCTION

Osteoma is slowly growing benign tumor composed of well- differentiated osseous tissue (1,2). Etiology is unknown, yet theories discuss congenital origin, embryogenesis, trauma, infection, metaplasia, inflammation, and hormones as possible etiologic factors (1,3-5). According to the site of origin, osteomas can be classified to peripheral (ones arising from periosteum), central (those which arise from endosteum) or extraskeletal (ones which appear within muscles) (4,6,7). Furthermore, they can be divided into those composed of compact bone, cancellous bone or their combination (3,4). Appearance usually involves craniofacial bones (mandible, and paranasal sinuses), while uncommon locations include:

larynx, tongue, neck, middle ear, and temporal bone (6). Occurrence is more often in males, especially in young adults (2). We present a case of uncommon osteoma location in the external auditory canal in a young male.

## CASE REPORT

A 26- year- old male attended an examination due to strong facial pain, hearing loss and pain in the left ear. According to anamnestic data, he has so far had no medical problems, underwent no surgical procedures, took no medication, exhibited no allergies, and denied ear trauma. During ear exploration, nontender, nonpulsatile mass characterized by firm consistency without signs of inflammation, which completely closed lumen of the left external auditory canal, was revealed. Multislice computed tomography (CT) of temporal bones demonstrated hyperdense content in the middle part of the left external auditory canal containing berry- shaped bony structures, 15 mm in length, and 8 mm in

\*Corresponding author: Svjetlana Marić, PhD, Professor, Department of Biology, Medical Faculty Osijek, University of Osijek, Osijek, Croatia. e-mail: maric.svjetlana@yahoo.com

Submitted: 19 June 2017/Accepted: 8 August 2017

DOI: <https://doi.org/10.17532/jhsci.2017.428>



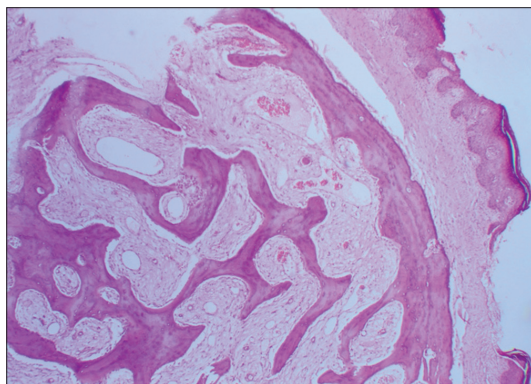
width. The patient underwent complete surgical removal of the bony mass due to functional disturbances caused by its presence in the external auditory canal. Segment of firm tissue, 15 mm in its largest diameter was received for pathohistological analysis. Decalcination, hematoxylin- eosin staining with an examination of the tissue sections followed, and revealed tumor consisted of mature trabecular bone covered by epidermis (Figure 1). Final diagnosis of osteoma of external auditory canal was established. Post-operative course passed without complications with patient's complete recovery, including hearing level in the affected ear and pain loss. He was discharged 4 days after surgery. No osteoma recurrence was observed during 12 months follow- up.

## DISCUSSION

Lesions arising from temporal bones are considered rare occurrence (8). Osteomas of external auditory canal are rare, but still most common tumors of temporal bones (8). Shah et al. report their incidence to be 0.05% of complete otologic surgery (9,10). We were not able to find specific data on the number of so far reported cases of external auditory canal osteoma in the available literature. Some of reported cases of this entity are presented in Table 1. Osteomas usually appear as unilateral asymptomatic lesions (11), which are most often incidentally found (4). They are treated as benign lesions prone to local growth without tendency of metastasis. Although characterized by slow growth (7), depending on their extension and anatomical localization, problems such as functional defects, facial asymmetry and pain, difficulties with occlusion, (7) or as in our patient, and hearing level deterioration, occur. Other possible symptoms related to osteoma presence in external auditory canal include vertigo and tinnitus (5). They can appear as part of Gardner's syndrome, which includes skin and mesentery fibromas, multiple osteomas, multiple intestinal polyps, and epidermoid inclusion cysts (1).

Osteoma visualization is possible by performing conventional radiograph, while computed tomography enables better demonstration and more precision during the process of lesion localization (3).

Differential diagnosis includes benign and malignant lesions such as exostoses, ossifying fibroma,



**FIGURE 1.** Histological section of bony tissue consisted of mature trabecular bones covered by epidermis (hematoxylin and eosin stain,  $\times 10$ ).

Paget's disease, osteosarcoma, chondroma, osteomyelitis, and fibrous dysplasia, which should be considered when examining the patient (4). Exostoses represent an entity that is more commonly seen in external auditory canal than osteoma (5,9). In the study of Pulec et al. (12), osteoma and exostoses are considered to be the same entity. However, they are mostly considered to be two different lesions. Osteomas are benign neoplasms of unknown etiology which appear as unilateral, single, pedunculated hyperdense mass on CT scan, and as lamellated bone with osteocytes surrounding fibrovascular channels on histology, yet exostoses are reactive lesions related to recurrent otitis externa and cold water exposure, with appearance of hyperdense, multiple, bilateral lesions characterized by broad base, and smooth borders on CT scan. Histologically, abundant osteocytes and parallel, concentric layers of subperiosteal bone can be observed. However, similarity between exostoses and osteomas lies in similar symptoms, benign nature and the fact that they are both usually discovered incidentally (5,9).

Treatment of osteomas includes complete surgical removal, which is considered necessary in case of symptomatic lesion, cosmetic reasons or tumor enlargement with functional defects (3) or unpleasant symptomatology, to diminish or remove symptoms and dysfunctions. In our patient's case, surgery was performed since tumor caused a disturbance in his life quality due to constant pain and hearing deterioration. According to available data,

**TABLE 1.** Reported cases of external auditory canal osteoma

References	Type of study	Patients	Symptoms	Diagnostic procedures	Treatment
Gheorghe et al. J Med Life. 2016;9:434-6.	Case study	15-year-old male	Hearing loss	Clinical examination, audiogram, CT scan, pathohistological analysis	Surgery on symptomatic ear through canal approach
Khoyratty et al. JSCR. 2013;6:1-4.	Case study	24-year-old female	Recurrent neck abscesses bony swelling arising from external ear canal	Clinical examination, pathohistological analysis	Incision and drainage of abscesses transmeatal excision of the external ear canal osteoma
Carbone et al. Head and Neck Pathol. 2012;6:244-6.	Case study	28-year-old male	Ear mass incidentally found during a routine audiology evaluation	Clinical examination, CT scan, pathohistological examination	Surgical excision through the external auditory meatus
Bahgat et al. BMJ Case Rep. 2012; doi: 10.1136/bcr-2012-006745.	Case study	40-year-old female	Progressive hearing loss	Physical examination, CT scan, audiometry, pathohistological analysis	Surgical removal
Liu et al. Lin Chung Er Bi Yan Hou Tou Jing Wai Ke Za Zhi. 2012;26:611-2.	Retrospective study	26 patients	Conductive hearing loss	Clinical examination, CT scan, pathohistological analysis	Surgical removal through interauricular approach
Kuczkowski et al. Otolaryngol Pol. 2010;64:365-9.	Retrospective study	21 patients	Conductive hearing loss+sensorineural component	Clinical and radiological examination, audiometry, pathohistological examination	Surgical removal through intrauricular approach
Sente. Srp Arh Celok Lek. 2009;173:73-6.	Case study	70-year-old patient	Incidentally found during otoscopic examination	Physical examination, CT scan, audiometry, pathohistological analysis	Surgical removal by retroauricular approach

CT: Computed tomography

osteoma recurrence is rare event in case the lesion is adequately surgically treated (3). For asymptomatic patients, only follow-up is recommended (5). We consider recognition of this benign entity important, since correct diagnosis determines treatment procedures.

Osteoma in external auditory canal is uncommon, yet it presents benign lesion which requires only surgical treatment based on complete removal of the lesion and patient follow-up (13). No reports of its malignant transformation have so far been recorded (3). Nevertheless, this entity should be taken into consideration, and distinguished from other possible conditions, especially malignant ones, to adequately inform and treat the patient, but also, to avoid progress of unpleasant symptomatology.

### CONFLICT OF INTEREST

The authors declare no conflict of interest.

### REFERENCES

1. Abdel Tawab HM, Kumar VR, Tabook SM. Osteoma presenting as a painless solitary mastoid swelling. *Case Rep Otolaryngol* 2015;2015:590783. <https://doi.org/10.1155/2015/590783>.
2. Kim DY, Oh KS. A rare case of peripheral osteoma of the zygoma. *Arch Plast Surg* 2015;42(1):103-5. <https://doi.org/10.5999/aps.2015.42.1.103>.
3. Batra N, Batra R, Singh G, Gaur A. Peripheral osteoma of maxilla: A case report. *Natl J Maxillofac Surg* 2014;5(2):240-2. <https://doi.org/10.4103/0975-5950.154848>.
4. Dell'Aversana Orabona G, Salzano G, Iaconetta G, Piombino P, Ponzio L, Santella A, et al. Facial osteomas: Fourteen cases and a review of literature. *Eur Rev Med Pharmacol Sci* 2015;19(10):1796-802.
5. Carbone PN, Nelson BL. External auditory osteoma. *Head Neck Pathol* 2012;6(2):244-6. <https://doi.org/10.1007/s12105-011-0314-7>.
6. Hagiwara A, Nagai N, Ogawa Y, Suzuki M. Osteoma of the pharynx that developed from the hyoid bone. *Case Rep Otolaryngol* 2014;2014:732096. <https://doi.org/10.1155/2014/732096>.
7. Sasidharan A, Gohil A, Koshy S, Gupta AK. Bony tumour in an unusual location on the mandible. *Indian J Plast Surg* 2015;48(2):200-3. <https://doi.org/10.4103/0970-0358.163062>.
8. Curtis K, Bance M, Carter M, Hong P. Middle ear osteoma causing progressive facial nerve weakness: A case report. *J Med Case Rep* 2014;8:310. <https://doi.org/10.1186/1752-1947-8-310>.
9. Shah S, Chetri ST, Manandhar S, Pokhrel A, Aryal B, Prakash A. Osteoma of the external auditory canal masquerading as an aural polyp: Case report and review of literature. *Am J Med Case Rep* 2013;1(1): 3-5.
10. Gheorghe DC, Stanciu AE, Ulici A, Zamfir-Chiru-Anton A. Bilateral external ear canal osteomas-discussion on a clinical case. *J Med Life* 2016;9(4):434-6.
11. Yorgancılar E, Kinis V, Gün R, Bakır S, Ozbay M, Topçu I. External auditory canal osteoma resulting in cholesteatoma which is complicated with meningitis. *Kulak Burun Bogaz İhtis Derg* 2013;23(1):44-7. <https://doi.org/10.5606/kbbihtisas.2013.78790>.
12. Pulec JL, Deguine C. Osteomas of the external auditory canal. *Ear Nose Throat J* 1993;72(2):112.
13. Bahgat M, Bahgat Y, Bahgat A, Aly S. External auditory canal osteoma. *BMJ Case Rep* 2012;2012. pii: Bcr2012006745.