



Bilateral tunnel vision as the first presenting sign of levamisole-induced vasculitis

Maria Sofia Cotelli^{1*}, Gina Alessandra Gregorini², Doriana Polonioli¹, Marinella Turla¹

¹Department of Neurology, Neurological Unit, ASST Valcamonica-Esine, Brescia, Italy, ²Department of Nephrology, ASST Spedali Civili, Brescia, Italy

ABSTRACT

Levamisole-contaminated cocaine is an increasingly reported cause of a syndrome characterized by vasculitic skin lesions and immunologic abnormalities. With approximately 70% of cocaine in the United States now contaminated with levamisole, the incidence of this syndrome is likely to increase. We report the case of a 42 years-old Caucasian woman who presented with fronto-temporal pulsating headache and progressive bilateral loss of vision.

Key words: levamisole; vasculitis; cocaine

INTRODUCTION

Levamisole-contaminated cocaine is an increasingly reported cause of a syndrome characterized by vasculitic skin lesions and immunologic abnormalities. With approximately 70% of cocaine in the United States now contaminated with levamisole, the incidence of this syndrome is likely to increase.

CASE REPORT

We report the case of a 42-year-old Caucasian woman who underwent our observation due to frontotemporal pulsating headache and progressive bilateral loss of vision with the inability to see in dim light or at night (nyctalopia), lasting for 1 month.

Medical and social history was positive for chronic cocaine abuse, high alcohol intake, previous right retinal hemorrhage, and hospitalization for pericarditis and paroxysmal supraventricular tachycardia. Neurological examination resulted in normal findings except for bilateral tunnel vision (Figure 1). The patient underwent brain computed tomography (CT), magnetic resonance imaging (MRI), and magnetic resonance angiography (angio-MRI) which were within normal limits (Figure 2). In addition, maxillofacial CT was performed showing chronic sinusitis and chronic parodontopathy, resulting from previous nasal septum perforation. Visual field testing showed bilateral centrocecal scotomas. Nasal septum biopsy showed necrosis and chronic mucositis. Optical coherence tomography displayed bilateral thinning of temporal fibers. Blood examinations showed high titer of antineutrophil cytoplasmic antibodies (ANCA): pANCA/MPO, 85.7 (normal values negative); anti-nuclear antibodies 1:80 (normal values negative); slight increase of end-systolic

*Corresponding author: Maria Sofia Cotelli, Neurological Unit ASST Valcamonica, Via Manzoni 142, Esine, Brescia, Italy. E-mail: cotellim@gmail.com

Submitted: 12 January 2018/Accepted: 30 March 2018

DOI: <https://doi.org/10.17532/jhsci.2018.517>



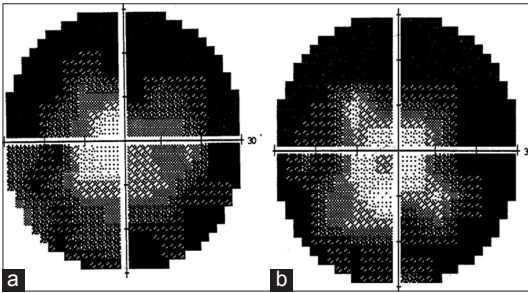


FIGURE 1. Bilateral tunnel vision in levamisole-induced vasculitis. (a) Visual field left eye, (b) visual field right eye.

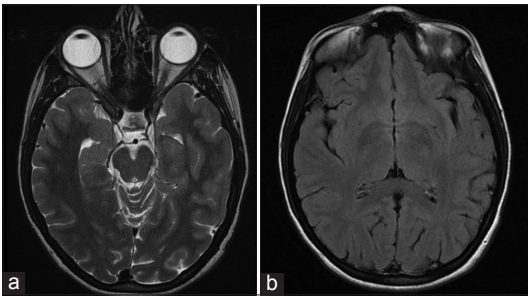


FIGURE 2. Brain magnetic resonance imaging (MRI) T2 (a) and MRI fluid attenuation inversion recovery (b) findings in levamisole-induced vasculitis.

volume of 50 mm (normal range 1–32 mm), and RCP of 70.1 (normal value <5). Both complete blood count and renal function parameters were normal. Urine toxicological tests were positive for cocaine. Levamisole was not tested.

Prednisone 1 mg/kg/daily was initiated. After 1 month of therapy, there was an improvement in the general condition an improvement of general condition with consequent reduction of the dose. The patient was devoid of cocaine during the therapy.

DISCUSSION

Levamisole is a synthetic imidazothiazole derivative which was originally marketed as an anthelmintic agent but was also found to have major immunomodulatory properties (1). It induced interferon synthesis and synergized the effect of steroids and other immunosuppressants (2). It was used in cancer therapy such as colon and breast cancer or to treat various immunological renal diseases, such as

pediatric nephrotic syndrome. Further, it was used to treat a number of skin diseases, including Behçet’s disease and rheumatoid arthritis. However, the drug was withdrawn from the market in the United States in 2000 and in Canada in 2003 because of serious side effects. It is still available as a veterinarian deworming drug in the United States and South America (2,3).

The mechanism of the action of levamisole as an antiparasitic agent appears to be tied to its agonistic activity toward the L-subtype nicotinic acetylcholine receptors in nematode muscles. This agonistic action reduces the capacity of the males to control their reproductive muscles and limits their ability to copulate (4).

The effects of levamisole on the immune system are complex. The drug appears to restore depressed immune function rather than to stimulate the response to above normal levels (4). Levamisole can stimulate the formation of antibodies to various antigens, enhance T-cell responses by stimulating T-cell activation and proliferation, potentiate monocyte and macrophage functions including phagocytosis and chemotaxis, and increase neutrophil mobility, adherence, and chemotaxis (5).

Levamisole is readily absorbed from the gastrointestinal tract and metabolized in the liver. It achieves peak plasma concentration in 1.5–2 h (6). Its plasma elimination half-life is 3–4 h, which is fairly short and may often be the reason for negative toxicological tests that detect levamisole (7). Levamisole rapidly metabolizes to aminorex and related metabolites, which have a half-life of about 16 h (6,8). Levamisole excretion is primarily through the kidneys, with about 70% being excreted over 3 days (5). Only about 5% is excreted as unchanged levamisole (7).

Aminorex is an amphetamine-like agent that was detected in racehorses after levamisole administration (8). Aminorex was marketed as an appetite suppressant in the mid-1960s mainly in Switzerland, Austria, and Germany; it was found to cause pronounced vasoconstriction in the pulmonary vasculature and was withdrawn in 1972 due to several cases of fatal and life-threatening pulmonary hypertension (8).

Levamisole has also been recognized as an adulterant in illicit cocaine since 2003. A 2009 national

TABLE 1. Levamisole common effects on the human body

Levamisole manifestations	Literature review
Dermatological involvement	
Erythema elevatum diutinum-Like vasculitis	Ewan et al. 2018
Vanishing vasculitis	Ghias et al. 2018
Generalized fatal vasculitis	Hammond et al. 2017
Pyoderma gangrenosum	Seghal R et al. 2017 Jeong et al. 2016
Retiform purpura	Nelson N et al. 2016 Walsh NM et al. 2010 Han et al. 2011
Eyelid necrosis and secondary cicatricial ectropion	Ramesh et al. 2017
Delayed recurrent vasculitis with varying vasculitic antibodies over the years.	Yogarajah 2015
Facial necrosis	Formeister et al. 2015
Intestinal involvement	
Ileal intussusception	van der Veer et al. 2017
Bowel ischemia	Khan et al. 2018
Osteoscheletrical involvement	
Arthralgia and myalgia	van der Veer et al. 2017
Extremity bone necrosis with amputation	Ching 2012
Otolaryngologic manifestation	
Otolaryngologic manifestations	Alemi et al. 2016
Cardiopulmonary involvement	
Acute coronary syndrome	Michaud et al. 2014
Isolated pulmonary vasculitis	Karch 2016
Central nervous system involvement	
Multifocal inflammatory leukoencephalopathy	Vitt JR et al. 2017 Vosoughi and Schmidt
Recurrent leukoencephalopathy	González-Duarte and Williams
Peripheral nervous system involvement	
Myopathy	Tsai et al. 2013
Renal involvement	
Nephrotic syndrome	Alvarez Diaz et al. 2013
Crescentic glomerulonephritis	Chawdhary K et al. 2015 Carrara et al. 2016
Membranous nephropathy	Moinuddin et al. 2016
Spontaneous renal artery bleed	Machua et al. 2016
Pancreatic involment	
Acute pancreatitis	Ogunbameru et al. 2015
Atypical generalized pattern	
Pseudovasculitis	Fan et al. 2017

survey found that approximately 70% of cocaine in the USA is contaminated with levamisole (9). It is added to cocaine because it potentiates its stimulant effects by inhibiting both monoamine oxidase and catechol-O-methyltransferase activity, thereby prolonging the action of catecholamines in the neuronal synapse and increasing the reuptake inhibition effect of cocaine (4).

The concentration of levamisole in cocaine has steadily increased since it was first detected. The concentration

was <1% in 2001, and in 2009, levamisole comprised approximately 10% of each cocaine sample. In an analysis of cocaine users in Seattle, Washington, approximately 80% of users who tested positive for cocaine also tested positive for levamisole (10). Levamisole is also used to adulterate other illicit substances; seized heroin supplies in 2008 and 2009 were found to contain trace amounts of levamisole (10).

Furthermore, aminorex was detected in human urine samples in a multitude of cocaine abusers. It seems to

TABLE 2. Hematological and laboratory findings in levamisole vasculitis

Haematological features	Frequency of presentation (%)	Literature review
Leukopenia	28% of patients	Cascio ML <i>et al.</i> 2018 Dezman Z <i>et al.</i> 2016 Cherlopalle <i>et al.</i> 0016
Agranulocytosis/neutropenia		Khan MS <i>et al.</i> 2018 Kassim T <i>et al.</i> 2018 Srivastava R <i>et al.</i> 2017
Anemia	73% of patients	García MR Pérez <i>et al.</i> 2013 Cascio <i>et al.</i> 2018
Thrombocytopenia	10% of patients	Cascio ML <i>et al.</i> 2018 Martinez <i>et al.</i> 2016
Laboratory findings		
CRP	Elevated in 82.4% of patients	Dartevel 2018
ANA	Positive in 57% of patients raging from 140 to 11280, mostly homogeneous pattern	Cascio <i>et al.</i> 2018
Anti-DNA	Positive in 23% of patients s raging from 110 to 1160	Cascio ML <i>et al.</i> 2018
ANCA	Positive in 93.8% of patients	Cascio ML <i>et al.</i> 2018
	Positive in 85% of patients	Dartevel A <i>et al.</i> 2018
MPO	Positive in 32.2% of patients	Dartevel A <i>et al.</i> 2018
PR3	Positive in 15.3% of patients	Dartevel <i>et al.</i> 2018
LAC	Positive in 42.3% of patients	Dartevel A <i>et al.</i> 2018
	Positive in 73% of patients	Cascio ML <i>et al.</i> 2018
Anti cardiolipin	Positive in 24% (IgM), 14% (IgG) of patients	Cascio <i>et al.</i> 2018
Anti-beta 2 GPI		
C3	Both decreased in 16.1% of patients	Dartevel <i>et al.</i> 2018
C4		
Cryoglobulin	Detected in about 19% of patients	Dartevel <i>et al.</i> 2018

CRP: C-reactive protein), ESR: Erythrocyte sedimentation rate, ANA: Anti-nuclear Ab annti, DNA: Anti-deoxyribonucleic acid (anti-DNA), ANCA: Anti-neutrophil cytoplasmic antibodies, anti MPO: Anti-myeloperoxydase, PR3: Anti-proteinase 3, LAC: Lupus anticoagulant, Anti beta 2 GPI: Anti-β2 glycoprotein 1, IgM: Immunoglobulin M, IgG0: Immunoglobulin G

exert strong effects on all three neurotransmitter monoamine transporters such as serotonin, norepinephrine, and dopamine in a manner similar to amphetamine (8). Levamisole-induced vasculitis (LIV) was first described in the 1970s (11). LIV is a cutaneous vasculitis that has been reported with smoked crack cocaine and inhaled cocaine powder. It has a greater frequency in women (male-to-female ratio 1:3), with a mean age of presentation of 44 years (1,11). It is characterized by skin involvement, especially necrotic purpura located in the ears, leukoneutropenia, ANCAs, and/or anti-phospholipid Abs and good prognosis on levamisole cease. Although other compounds can be added to cocaine, vasculitis has been associated with long-term use of cocaine mixed with stimulants such as levamisole (12). Patients with LIV develop tender purpuric lesions 1–3 days

after exposure (12). These lesions first develop as symmetric erythema, evolve into retiform purpura and bullae, and finally undergo necrosis and eschar formation (12). Most commonly, lesions develop over the ear, malar eminences, and tip of the nose. Diagnosis of LIV is on its clinical presentation and histopathological findings of leukocytoclastic vasculitis of small vessels containing fibrinous necrosis of the vessel wall, erythrocyte extravasation, and multiple fibrin thrombi within small vessels in the superficial and deep dermis (12).

Other recognized manifestations among cocaine abusers are pulmonary-renal syndrome (13), multifocal recurrent leukoencephalopathy with diffuse white matter involvement with sparing of the U fibers, without brain stem or cerebellar involvement (14,15), pyoderma gangrenosum (16), intravascular thrombosis,

and less commonly crescentic nephritis, retiform purpura, and pauci-immune glomerulonephritis (17,18). Common side effects are shown in Table 1, while common laboratory values are presented in Table 2.

Bilateral tunnel vision has been described in various ocular diseases, such as retinitis pigmentosa (19), choroideremia (20), and glaucoma (21), but has never been described before as a presenting sign for levamisole vasculitis.

CONCLUSION

We described a case of levamisole-adulterated cocaine vasculitis with atypical symptoms of presentation, such as headache and bilateral tunnel vision, both improved after discontinuing cocaine abuse and starting treatment with prednisone. We think that expand literature for this entity helps specialists to considerate levamisole adulteration as a possible differential diagnosis when evaluating ocular signs in cocaine abuser patient. We think that bilateral tunnel vision can be considered as a manifestation of small vessel vasculitis with bilateral temporal fibers thinning, while headache can be considered a side effect of both chronic cocaine and levamisole abuse.

REFERENCES

1. Strazzula L, Brown KK, Brieva JC, Camp BJ, Frankel HC, Kissin E. Levamisole toxicity mimicking autoimmune disease. *J Am Acad Dermatol* 2013;69(6):954-9. <https://doi.org/10.1016/j.jaad.2013.07.037>.
2. Abdul-Karim R, Ryan, C, Rangel C, Emmett M. Levamisole induced vasculitis Proc. *Baylor Univ Med Cent* 2013;26(2):163-5. <https://doi.org/10.1080/08998280.2013.11928946>.
3. Berman M, Paran D, Elkayam O. Cocaine-induced vasculitis rambam Maimonides. *Med J* 2016;7(4):e0036.
4. Goldstein G. Mode of action of levamisole. *J Rheumatol Suppl* 1978;4:143-8.
5. Carrara C, Emili S, Lin M Alpers CE. Necrotizing and crescentic glomerulonephritis with membranous nephropathy in a patient exposed to levamisole-adulterated cocaine. *Clin Kidney J* 2016;9(2):234-8. <https://doi.org/10.1093/ckj/sfv141>.
6. Chang A, Osterloh J, Thomas J. Levamisole: A dangerous new cocaine adulterant. *Clin Pharm Ther* 2010;88:408. <https://doi.org/10.1038/clpt.2010.156>.
7. Trehy ML, Brown DL, Woodruff JT, Westenberger BJ, Nychis WG, Reuter N. Determination of levamisole in urine by gas chromatography-mass spectrometry. *J Anal Toxicol* 2011;35(8):545-50. <https://doi.org/10.1093/anatox/35.8.545>.
8. Hofmaier T, Luf A, Seddik A, Stockner T, Holy M, Freissmuth M. Aminorex, a metabolite of the cocaine adulterant levamisole, exerts amphetamine like actions at monoamine transporters. *Neurochem Int* 2014;73(2):32-41. <https://doi.org/10.1016/j.neuint.2013.11.010>.
9. Casale JF, Corbeil EM, Patrick AH. Identification of levamisole impurities found in illicit cocaine exhibits. *Microgram J* 2008;6(3-4):82-9.
10. Lee KC, Ladizinski B, Federman DG. Complications associated with use of levamisole-contaminated cocaine: An emerging public health mayo. *Clin Proc* 2012;87(6):581-6. <https://doi.org/10.1016/j.mayocp.2012.03.010>.
11. Roberts JA, Chévez-Barrios P. Levamisole-induced vasculitis: A characteristic cutaneous vasculitis associated with levamisole-adulterated cocaine. *Arch Pathol Lab Med* 2015;139(8):1058-61. <https://doi.org/10.5858/arpa.2014-0107-RS>.
12. Sayadi L, Laub D. Levamisole-Induced Vasculitis. *Eplasty* 2018;18:ic5.
13. Restrepo-Escobar M, Sylva D, Gamboa JG, Echeverri A, Márquez J, Pinto LF. Pulmonary-renal syndrome secondary to cocaine-levamisole-induced vasculitis: A case report. *Reumatol Clin* 2018;2018: pii: S1699-258X.
14. González-Duarte A, Williams R. Cocaine-induced recurrent leukoencephalopathy. *Neuroradiol J* 2013;26(9):511-3. <https://doi.org/10.1177/197140091302600503>.
15. Vosoughi R, Schmidt BJ. Multifocal leukoencephalopathy in cocaine users: A report of two cases and review of the literature. *BMC Neurol* 2015;15:208. <https://doi.org/10.1186/s12883-015-0467-1>.
16. Jeong HS, Layher H, Cao L, Vandergriff T, Dominguez AR. Pyoderma gangrenosum (PG) associated with levamisole-adulterated cocaine: Clinical, serologic, and histopathologic findings in a cohort of patients. *J Am Acad Dermatol* 2016;74(5):892-8. <https://doi.org/10.1016/j.jaad.2015.11.040>.
17. Carlson AQ, Tuot DS, Jen KY, Butcher B, Graf J, Sam R, et al. Pauci-immune glomerulonephritis in individuals with disease associated with levamisole-adulterated cocaine: A series of 4 cases. *Medicine* 2014;93(17):290-7. <https://doi.org/10.1097/MD.0000000000000090>.
18. Veronese FV, Dode RS, Friderichs M Thomé GG, da Silva DR, Schaefer PG. Cocaine/levamisole-induced systemic vasculitis with retiform purpura and pauci-immune glomerulonephritis. *Braz J Med Biol Res* 2016;49(5):e5244. <https://doi.org/10.1590/1414-431X20165244>.
19. Audere M, Rutka K, Šepetiene S, Låce B. Presentation of complex homozygous allele in ABCA4 gene in a patient with retinitis pigmentosa. *Case Rep Ophthalmol Med* 2015;2015:452068.
20. Woods RL, Giorgi RG, Berson EL, Peli E. Extended wearing trial of trifield lens device for "tunnel vision". *Ophthalmic Physiol Opt* 2010;30(3):240-52. <https://doi.org/10.1111/j.1475-1313.2010.00718.x>.
21. Hu CX, Zangalli C, Hsieh M, Gupta L, Williams AL, Richman J, et al. What do patients with glaucoma see? Visual symptoms reported by patients with glaucoma. *Am J Med Sci* 2014;348:403-9. <https://doi.org/10.1097/MAJ.0000000000000319>.