



Bilateral inferior conchae and turbinate hypertrophy causing choanal pseudoatresia

Wan Nabila Wan Mansor^{1*}, Azrina Ahmad², Jeyanthi Kulasegarah³

¹Department of Otorhinolaryngology-Head and Neck Surgery, Universiti Kebangsaan Malaysia, Jalan Yaacob Latif, Jalan Tun Razak, 56000, Batu 9, Cheras, Kuala Lumpur, Malaysia, ²Department of Otorhinolaryngology, Faculty of Medicine, Universiti Teknologi Mara, Jalan Hospital, 47000, Sungai Buloh, Selangor, Malaysia, ³Department of Otorhinolaryngology, Universiti Malaya 50603, Kuala Lumpur, Malaysia

ABSTRACT

Respiratory distress in neonates is an emergency which requires a thorough investigation to determine the cause, whether it is due to the upper respiratory or lower respiratory entity. Nasal cavity pathologies rarely compromise the neonatal airway. Newborns are obligatory nasal breathers; thus, upper respiratory tract problems could potentially become life-threatening. We report a case of a newborn boy with inferior turbinate hypertrophy (ITH) causing respiratory distress treated successfully by nasal dilatation and posterior septoplasty. Congenital bilateral ITH is rarely seen and can mimic choanal atresia. Congenital ITH would be missed at initial presentation without radiographic imaging and physical evaluation. It should be considered as one of the differential diagnosis in cases suspected for choanal atresia.

Key words: Respiratory distress; congenital inferior turbinate hypertrophy; choanal atresia

INTRODUCTION

Nasal obstruction is a common presentation in pediatric otorhinolaryngology (1). Bilateral nasal obstruction in neonates is a fatal condition since neonates are obligatory nasal breathers (2). Choanal atresia is a well-known nasal cavity anomaly, while choanal stenosis, congenital nasal mid-line masses, congenital nasal pyriform aperture stenosis, and inferior turbinate hypertrophy (ITH) are more rarely seen (3). ITH in the pediatric population is commonly

an acquired problem rather than congenital (1). Congenital ITH is rarely seen, and its presentation is similar to other nasal obstruction causes in neonates, which include respiratory distress and feeding problems (1). ITH can be caused by bony hypertrophy with normal mucosa, as a result of a traumatic development and hypertrophy with abnormal thickening of the mucosa of the turbinate, which could be due to edema in acute or chronic inflammation (4). Surgery is usually reserved for bony abnormalities and mucosal congestion unresponsive to treatment (5). There is a paucity of references that specifically address congenital ITH and limited literary guidance regarding the management of this condition (1). Despite congenital ITH being a rare condition, unfamiliarity with the presentation can lead to misdiagnosis with choanal atresia due to the anatomic relations and similar clinical presentation.

*Corresponding author: Wan Nabila Wan Mansor, Department of Otorhinolaryngology-Head and Neck Surgery, Universiti Kebangsaan Malaysia, Jalan Yaacob Latif, Jalan Tun Razak, 56000, Batu 9, Cheras, Kuala Lumpur, Malaysia.
E-mail: wannabila.wanmansor@gmail.com

Submitted: 18 June 2018 / Accepted: 25 September 2018

DOI: <https://doi.org/10.17532/jhsci.2018.581>



CASE REPORT

A newborn baby boy delivered through the elective cesarean section in view of fetal macrocephaly which was diagnosed antenatally by maternal-fetal medicine specialist. Ultrasound scan during pregnancy revealed dilatation of left brain ventricles and absence of cavum septum pellucidum with the single umbilical artery, echogenic bowel, and mild right pelvicalyceal dilatation. The child was delivered with an APGAR score of 4 at 1 min and nine at 5 min. On delivery, the child became acrocyanosis with poor respiratory effort. Positive pressure ventilation was given; however, reassessment showed worsening tachypnea with the subcostal recession, thus, warranted for endotracheal intubation. The child was successfully intubated with endotracheal tube (ETT) size 3.5. There was an inability to pass a transnasal catheter through the bilateral nostrils. The general physical assessment confirmed the presence of macrocephaly, single umbilical artery, and sacral dysraphism with clinically suspected choanal atresia. Axial view of computerized tomography (CT) scan demonstrated narrowed nasal passages from anterior to posterior nasal cavity with thickened vomer and facial bone hypoplasia (Figure 1). Coronal view of the CT scan shows nasal stenosis with ITH (Figure 2). Nasal endoscopy revealed bilateral ITH causing complete nasal stenosis with patency of posterior nasal choanae. The nasal passage was dilated with urethral sound and stent insertion with modified ETT was done. Second nasal passage dilatation and posterior septoplasty (partial vomer removal) were required as bilateral stents blockage occurred after the first procedure. Postoperatively, the patient is well and able to wean from mechanical ventilation. The patient was discharged home with nasal care instructions and regular neurosurgical follow-up.

DISCUSSION

Nasal obstruction in neonates is a respiratory emergency because newborn babies are obligate nasal breathers. However, infants can develop the reflex to breathe through open mouth in response to nasal obstruction in between weeks and months after birth. However, they can readily mouth breathe if the mouth is opened during crying (6). Congenital

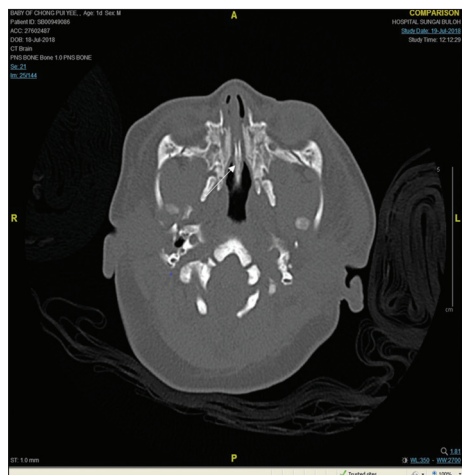


FIGURE 1. Axial view of computerized tomography scan shows a stenosed nasal cavity with thickened vomer (arrow).

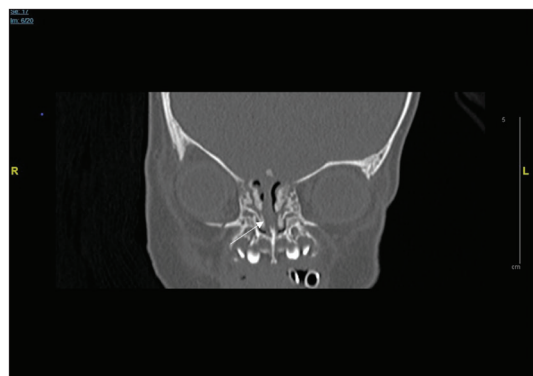

FIGURE 2. Coronal view of the computerized tomography scan shows inferior turbinate hypertrophy causing stenosed nasal cavity (arrow).

ITH is a rare cause of neonatal nasal obstruction (1). This condition and other types of nasal pathologies such as choanal atresia rarely compromise the neonatal airway. Nevertheless, this case illustrates that congenital ITH can be the cause of significant respiratory compromise and morbidity in a neonate. While choanal atresia is one of the best-known nasal cavity anomalies, choanal stenosis, congenital nasal mid-line masses, and congenital nasal pyriform aperture stenosis, and nasal tip anomalies are other causes of neonatal upper respiratory obstruction (3). A thorough examination should be done to differentiate these nasal pathologies. ITH is generally an acquired problem and is encountered in response

to mucosal irritation from meconium rhinitis or gastroesophageal reflux in neonates (1). Otherwise, in children, an enlarged turbinate may be due to a deviated nasal septum and growth asymmetry or resulted from trauma (5). There are two pathological processes that lead to ITH which are cellular hyperplasia or hypertrophy causing bone expansion within the turbinate or cellular hypertrophy causes mucosal enlargement (5). Conventionally, the failure to pass a soft transnasal catheter in a suspected case of neonatal nasal obstruction can be considered diagnostic of congenital choanal atresia although the turbinate or adenoids may obstruct the passage (6). The absence of misting on a metal spatula, movement of a wisp of cotton wool in front of the nostrils and auscultation over the nostrils to assess airflow patency can be utilized as means of clinical examination which prompt high suspicion of neonatal nasal obstruction (6). However, the current investigation of choice is the combination of nasal endoscopy and CT scanning (6). Surgical treatment for ITH aims to maximize nasal airflow while concurrently preserving physiologic mucosal function (1). There is a controversy regarding any type of the surgery on the pediatric inferior turbinate, and this issue is also contributed by the lack of literature in relation to congenital ITH causing significant nasal obstruction (1,5). Therefore, further studies are required to establish comprehensive management of this condition.

CONCLUSION

Congenital ITH is a rare cause of neonatal nasal obstruction with the similar presentation as other nasal congenital problems that can cause respiratory distress in neonates. It warrants a thorough medical evaluation, with a focus on respiratory compromise and impairment of feeding. There is a poor evidence-based surrounding inferior turbinate surgery in neonates. Thus, further studies should be done to support the current practices.

CONFLICT OF INTERESTS

None.

REFERENCES

1. Kwok J, Leong MK, Koltai P. Congenital inferior turbinate hypertrophy: An unusual cause of neonatal nasal obstruction. *Int J Pediatr Otorhinolaryngol* 2007;2(1):26-30.
<https://doi.org/10.1016/j.pedex.2006.11.004>.
2. Jašić M, Ražem MM, Štrk I, Barbarić I. Bilateral choanal atresia in newborn infant. *Med Fluminensis* 2016;52(2):241-3.
3. Başal Y, Akcan AB, Polat YD, Günel C, Eryılmaz A, Başak S, et al. Rarely seen nasal congenital problems causing neonatal upper respiratory obstruction: A case series. *Pediatr Rep* 2016;8(1):6456.
<https://doi.org/10.4081/pr.2016.6456>.
4. Cury R, Gioseffi C, Andrade E, Cury M, Cury SE. The incidence of inferior turbinate hypertrophy in a Brazilian population. *Webmed central. Rhinology* 2013;4(6):WMC004276.
5. Leong SC, Kubba H, White PS. A review of outcomes following inferior turbinate reduction surgery in children for chronic nasal obstruction. *Int J Pediatr Otorhinolaryngol* 2010;74(1):1-6.
<https://doi.org/10.1016/j.ijporl.2009.09.002>.
6. Abdullah B, Hassan S, Salim R. Transnasal endoscopic repair for bilateral choanal atresia. *Malays J Med Sci* 2006;13(2):61-3.