



Anatomical variation of the thyroid gland – Levator glandulae thyroideae

Natalia M. Velasco-Nieves¹, Adegbenro Omotuyi John Fakoya^{2*}, Shannon Mathew¹, Wirda Zafar¹, Mahrukh Zafar¹, Kevin Alonso Milla¹, Sushanth Yerra¹, Abayomi Gbolahan Afolabi², Thomas McCracken²

¹University of Medicine and Health Sciences, Basseterre, St. Kitts and Nevis, ²Department of Anatomy, University of Medicine and Health Sciences, Basseterre, St. Kitts and Nevis

ABSTRACT

Surgical procedures are usually the treatment of choice when managing severe neck and thyroid-related pathologies; however, they become complicated by damage to the parathyroid glands, the external branch of superior laryngeal nerves, inferior laryngeal nerves, and hematoma due to vascular injury and the chance of residual thyroid tissue being left in case of cancer and Graves' disease, and the presence of anatomical variations. Therefore, prior knowledge of the incidence of anatomic anomalies would ensure avoidance of such complications. In this study, we describe the presence of a levator glandulae thyroideae that could misguide surgeons during surgical procedures.

Keywords: Levator glandulae thyroideae; thyroid; hyopyramidalis; thyroidectomy; pyramidal lobe

INTRODUCTION

The thyroid gland is a butterfly-shaped endocrine organ located in the anterior compartment of the neck at the level C5 to T1 (1). It consists of two lateral lobes connected by a narrow bridge known as the isthmus. The thyroid gland is one of the most important endocrine organs and plays a significant role in regulating metabolism, blood calcium levels, growth, and development (1,2).

The size, shape, and structure of the thyroid gland vary among individuals based on gender, race, and age. Organogenesis of the thyroid gland occurs first

in comparison to other endocrine organs during the development of the embryo predisposing it to a wide range of anomalies such as the presence of pyramidal lobe and levator glandulae thyroideae (LGT), a fibromuscular band (3,4). Other anomalies involving the thyroid gland development include agenesis/absence of isthmus and persistence of the thyroglossal ducts (1,3). Among these anomalies, the persistence of thyroglossal ducts and the presence of a pyramidal lobe are common, whereas agenesis of isthmus and presence of LGT are rare and only a few cases have been reported of such anomaly in the scientific literature (5).

LGT is classified into five types based on their attachment patterns: Hyopyramidalis, thyreopyramidalis, thyreoglandularis, hyoglandularis, and tracheoglandularis (1,2,6). LGT is a fibromuscular band that extends from the pyramidal lobe in most cases and attaches to the hyoid bone located superiorly.

*Corresponding author: Adegbenro Omotuyi John Fakoya, Department of Anatomy, University of Medicine and Health Sciences, Basseterre, St. Kitts and Nevis. E-mail: afakoya@umhs-sk.net

Submitted: 24 March 2020/Accepted: 29 April 2020

DOI: <https://doi.org/10.17532/jhsci.2020.904>



In the case being discussed, we describe a hyopyramidalis LGT that was discovered during routine cadaveric dissection of head and neck region. In the literature, there have been other researchers that have reported a LGT originating from different sites (Table 1) (1,4,6,7,8,9).

CASE REPORT

During routine dissection of the neck of a 70-year-old male Caucasian cadaver, at the Department of Anatomy of the University of Medicine and Health Sciences, St. Kitts and Nevis, a LGT was identified. It was dissected carefully to look for any further attachments and innervations above and below it. A thin band of muscular fibers stretched from the upper middle border of the isthmus of the thyroid gland to

the body of the hyoid bone (Figure 1). This type of muscle fibers would fall into hyopyramidalis classification of LGT as the fibers were found to be extending from the pyramidal lobe and attached to the hyoid bone located above. No additional abnormalities were found on the left and right lobes of the thyroid gland.

DISCUSSION

Thyroid diseases are a common health disorder among endocrinopathies present in the world population. Most of these diseases such as goiter, thyrotoxicosis, adenoma, and carcinoma are usually associated with enlargement of the gland and require medical and surgical intervention (4).

Our cadaver presented with the LGT muscle arising from the superior border of the isthmus of the thyroid

TABLE 1. LGT origin reported in the literature

Authors	Classification (8,9)	Origin	Year	Reference
Loukas et al.	Hyopyramidalis; thyreoglandularis; hyoglandularis	Pyramidal lobe of thyroid gland – hyoid bone; thyroid cartilage – thyroid gland; isthmus of thyroid gland – hyoid bone	2008	(8)
Ranade et al.	Hyoglandularis	Isthmus of thyroid gland – hyoid bone	2008	(7)
Chaudhary	Hyoglandularis	Isthmus of thyroid gland – hyoid bone	2013	(1)
Muktyaz et al.	Hyoglandularis	Isthmus of thyroid gland – hyoid bone	2013	(4)
Sinha et al.	Hyoglandularis	Isthmus of thyroid gland – hyoid bone	2014	(6)
Present study	Hyopyramidalis	Pyramidal lobe of thyroid gland – hyoid bone	2019	-

LGT classification according to Mori (1964) (8,9)

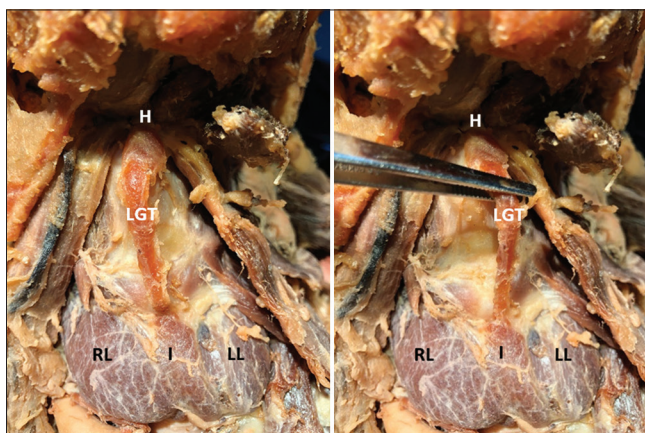


FIGURE 1. The levator glandulae thyroideae is a fibromuscular band or accessory muscle that originates from the isthmus of the thyroid gland and attaches to the body of the hyoid bone (hyopyramidalis (8,9)), as seen in these images. LGT: Levator Glandulae Thyroideae; I: Isthmus; LL: Left Lobe; RL: Right Lobe; H: Hyoid bone.

gland and attaching to the body of the hyoid bone. The presence of this accessory muscle gains importance in the pathologies which are related to the thyroid gland and their treatment modalities due to its proximity to the gland. Its occurrence is rare and only very few cases have been reported in the medical literature (1). Due to anatomical variations in the muscle tissues encompassing the thyroid organ, it is possible to cause iatrogenic wounds during neck and thyroid surgeries. In a study conducted to observe the thyroid glands of cadavers for the presence of a LGT, approximately 18.75% of the sample population were found to have LGT (10). The variations of the LGT can be associated with embryological disruption or anomalies. One such example of this is the failure of the thyroid gland to descend correctly and regression of the thyroglossal duct (3,11). This type of rare finding is essential to identify and acknowledge during surgical procedures carefully.

Eisler et al. conducted an extensive study regarding the innervation of LGT and concluded that the LGT must be innervated by either the ansa cervicalis or through the vagus nerve. Loukas et. al reported (2008) that their cadaver's LGT was innervated by a branch of the ansa cervicalis (8). However, according to a recent case report conducted by Chaudhary et al. (2013), LGT may have different origins regarding its innervation. Chaudhary et al. concluded, after a close examination of their cadaver in the study, that the LGT was innervated by branches of the external laryngeal nerve (1).

Loukas et al. discussed the possible embryological origin of the LGT depends on the location it must have derived from. He reported the following possible sites he found in literature: The cricothyroid muscle, the inferior pharyngeal constrictor muscle, mastoid process, hyoid bone, thyroid cartilage, and infrahyoid muscles, the last from which his cadaver's LGT was derived from according to its nerve supply. Since the thyroid gland is a highly vascularized structure, surgeons must be prepared to find this anatomical variation while carefully exploring to ensure safe surgical procedures, such as thyroidectomies (7,10). Therefore, it is essential to

have a thorough understanding of the anterior cervical region and its anatomical anomalies to avoid any major complications in head and neck surgeries.

CONCLUSION

A rare anatomical variation associated with the thyroid gland is the presence of a LGT. We presented a case of LGT during routine cadaveric dissection. We also demonstrate the developmental and surgical implication of the anomaly and the importance of having a thorough knowledge of anatomical variations to handle related clinical interventions with confidence.

REFERENCES

1. Chaudhary P. Levator glandulae thyroideae, a fibromusculoglandular band with absence of pyramidal lobe and its innervation: A case report. *J Clin Diagn Res* 2013;7(7):1421-4. <https://doi.org/10.7860/jcdr/2013/6144.3186>.
2. Pacifico FA, Filho GC, Marinho AJ, Felipe D. A variant topography of levator glandulae thyroideae: A Case report. *Int J Anat Var.* 2019;12(2):10-1.
3. Yadav A, Yadav M, Dixit A. A morphological study of levator glandulae thyroideae and pyramidal lobe in normal adult human thyroid gland. *Int J Res Health Sci* 2014;2(4):1030-3.
4. Muktyaz H, Birendra Y, Dhiraj S, Sharma A. Anatomical variations of thyroid gland and its clinical significance in north indian population. *Glob J Biol Agric Health Sci* 2013;2(2):12-6.
5. Prakash, Rajini T, Ramachandran A, Savalgi G, Venkata S, Mokhasi V. Variations in the anatomy of the thyroid gland: Clinical implications of a cadaver study. *Anat Sci Int* 2011;87(1):45-9. <https://doi.org/10.1007/s12565-011-0115-9>.
6. Sinha M, Siddiqui A, Sharma D. Levator glandulae thyroideae: A fibromusculoglandular band a case report. *Indian J Clin Anat Physiol* 2014;1:57-9.
7. Ranade A, Rai R, Pai M, Nayak S, Prakash, Krisnamurthy A, et al. Anatomical variations of the thyroid gland: Possible surgical implications. *Singapore Med J* 2008;49(10):831-4.
8. Loukas M, Merbs W, Tubbs RS, Curry B, Jordan R. Levator glandulae thyroideae muscle with three slips. *Anat Sci Int* 2008;83:273-6. <https://doi.org/10.1111/j.1447-073x.2007.00198.x>.
9. Mori M. Statistics on the musculature of the Japanese. *Okajimas Folia Anat Jpn* 1964;40:195-300. https://doi.org/10.2535/ofaj/1936.40.3_195.
10. Rajkonwar AJ, Kusre G. Morphological variations of the thyroid gland among the people of upper assam region of Northeast India: A cadaveric study. *J Clin Diagn Res* 2016;10(12):AC01-3. <https://doi.org/10.7860/jcdr/2016/19395.8966>.
11. Dessie M. Anatomical variations and developmental anomalies of the thyroid gland in Ethiopian population: A cadaveric study. *Anat Cell Biol* 2018;51(4):243. <https://doi.org/10.5115/acb.2018.51.4.243>.